

---

# TRANSYLVANIAN REVIEW

---

VOL XXV, No. 22, 2017



Transylvanian Review

Centrul de Studii Transilvane | str. Mihail Kogalniceanu nr. 12-14, et.5, Cluj-Napoca

Email: [transylvanianreview@gmail.com](mailto:transylvanianreview@gmail.com)

Online Submission System: <http://transylvanianreviewjournal.org/>

---

# Cyto and Genotoxic Effects of Zinc Oxide Nanoparticles on Testicular Tissue of Albino Rat and the Protective Role of Vitamin E

\*<sup>1</sup> Samir A. Nassar, <sup>2</sup> Omar I. Ghonemy, <sup>2</sup> Mohamed H. Awwad, <sup>2</sup> Marwa S.M. Mahmoud and <sup>2</sup> Yazed M.B. Alsagati

<sup>1</sup> Zoology Department, Faculty of Science, Zagazig University, Zagazig, Egypt and <sup>2</sup> Zoology Department, Faculty of Science, Benha University, Benha, Egypt

## Abstract

---

Background: Nanotechnology is a rapidly developing science, and the nanoparticles (NPs) application invaded several fields. However, safety of these NPs is still a subject of debate and there are raising concerns about their harmful environmental and health effects. The aim of the current study was to investigate the potential toxicity of ZnO- NPs on cellular morphology and function of testis in albino rat with reference to the possible protective role of vitamin E (Vit E). Methods: Fifty adult male albino rats were categorized equally into 5 groups. G1, control, G2, ZnO-NPs-intoxicated, G3, Vit E-administered, G4, Vit E + ZnO-co-administered and G5, recovery group. ZnO- NPs with a crystalline size of < 50 nm were administered orally for 5 consecutive days. Vit E was orally- administered for two consecutive weeks, one week before the start of the experiment. Histological, histomorphometric, immunohistochemical, molecular and biochemical markers were investigated to explore the protective extent of Vit E against ZnO-NPs- induced cyto-and genotoxicity in testis. Results: ZnO-NPs were incorporated by Leydig cells, Sertoli cells and other spermatogenic cells resulting in structural and functional alterations in testis via the induction of apoptosis. Damaged Leydig, Sertoli and spermatogenic cells, vacuolated interstitial tissue, reduced tubular diameter, increased collagen deposition in the extracellular matrix (ECM), reduced PCNA immunoexpression, increased DNA damage and decreased levels of testosterone were recorded. Co-administration of Vit E normalized the picture to a large extent. Conclusion: The recorded results confirmed the potential of ZnO- NPs to induce apoptosis in testicular cells with impairment for spermatogenesis and consequently male fertility. Vitamin E played a pivotal role in protecting the testicular tissue of rat against the toxicity of ZnO- NPs.

---

**Keywords:** ZnO nanoparticle, testicular cells, vitamin e, pcna, comet assay, rat.

---

\* Corresponding author: Samir A. Nassar, e-mail: sanassar@zu.edu.eg, Zoology Dept., Faculty of Science, Zagazig University, Zagazig, Egypt.

## Introduction

A particular attention was paid recently to the biological applications of ZnO NPs, including their use in cosmetics, medical devices, drug carriers, food additives, photodynamic therapy, and as biosensors. This broad spectrum of applications leads to increased human and environmental exposure to these NPs. Therefore, this elevated the potential risk due to their toxicity (Namvar *et al.*, 2015 and Saptarshi *et al.*, 2015). Nanoparticles toxicity was attributed to their tiny sizes, greater surface reactivity and ability to penetrate into and accumulate within cells (Mironava *et al.*, 2010). They can pass easily through cellular membranes, blood-testis barrier and blood-brain barrier (Yousefi *et al.*, 2013). Han *et al.* (2011) recorded neurotoxicity for ZnO-NPs in rats after intraperitoneal injection. Other studies have shown that ZnO-NPs could be harmful to human and other species (Guo *et al.*, 2013). ZnO- NPs has been categorized as testicular toxicant to the reproductive organs of male, (Talebi *et al.*, 2013). Vitamin E is an important antioxidant factor. It is commonly present in plant oils (germinating wheat), spices (paprika), seeds of sunflower and nuts. It is of a major role in protection (non-enzymatic) against lipid peroxidation in oxidative stress (Rikans *et al.*, 1991). Consequently, the elucidation of the possible harmful effects of ZnO-NPs on the structure of testis gives a chance to control the use of these Nano materials either by restriction or even preventing their use, the possible protective role of vitamin E may be alternative if their use becomes inescapable. Due to the scarcity of information concerning the reproductive toxicity of ZnO-NPs, the present study was designed to investigate the toxicity of ZnO-NPs in testicular cells from the histological, immunohistochemical, molecular and biochemical points of view, with special reference to the possible protective role of Vit E.

## Materials and Methods

### Chemicals

Zn O-NPs (< 50 nm size, MW: 81.39 g/mol, purity > 97% and toxic to aquatic life with long lasting effect) and vitamin E were products of Sigma-Aldrich Corporation (USA). All other chemicals used in the study were of high analytical grade and products of Sigma and Merck companies.

### Animals and Experimental Design

Fifty adult healthy male albino rats (150-180g) of *Rattus norvegicus* strain were obtained from the Animal Center of the Faculty of Veterinary Medicine, Zagazig University. Animals were housed in clean cages and maintained under standard conditions of light/dark cycle, temperature (23°C ±2) and humidity (60%). Rats were fed a standard pellet diet with free access to tap water. After 1 week of acclimation, animals were fasted over night before treatment and divided into five groups (10 rats each):

G1: Control group (healthy animals) nourished basal diet along the experimental period. G2-G5: Treated groups, orally- administered 1 g/kg B.W/day ZnO-NPs for 5 consecutive days (Wang *et al.*, 2008) and divided as follows, G2: ZnO-NPs intoxicated rats. G3: Vit E orally administered rats, 100 mg/kg/day (Sharma and Gupta, 2003), G4: ZnO-NPs intoxicated rats with co-administration of vitamin E daily and G5: ZnO-NPs-intoxicated rats and left to recover treatment for 21 days (Recovery group). Vit E was orally- administered daily (100 mg/kg BW/day) for two consecutive weeks, one week before the beginning of the experiment. After 24 hour of the last dose administration, rats were fasted overnight, euthanized, sacrificed and blood was collected. Sera were separated and kept at -80 °C for hormonal assessment. Testes were harvested and a number of them was fixed in 10% Neutral buffered formalin at room temperature for histopathological and immunohistochemical examination. Others were frozen at -80 °C for a molecular study (COMET assay).

### Histopathological Study

Tissue of testis after formalin fixation was dehydrated in serial dilutions of ethanol, cleared in xylene and embedded in melted paraffin wax at 58 degree centigrade in an oven. Paraffin tissue blocks were prepared for sectioning at 3-4 micron thickness by microtome. The obtained tissue sections were collected on glass slides, deparaffinized and processed for: Hematoxylin and eosin (H & E) staining (Levison *et al.*, 1996). Masson's trichrome staining for collagen (Pearse, 1977). Graphical filtration of trichrome-stained sections was done to demonstrate collagen deposition in the extracellular matrix of seminiferous tubules (Matter, 2017).

### Immunohistochemical Study

Neutral buffered formalin (10%) fixed testicular sections (5 µ thick) were dewaxed, hydrated to phosphate-buffered saline (PBS, pH 7.5). Immunostaining of PCNA was carried out using streptavidin/biotin immunoperoxidase method (LSAB kit, Dako Corp). Sections were immersed in 3% H<sub>2</sub>O<sub>2</sub> to calm down the activity of endogenous peroxidase and then incubated with PBS containing 1% bovine serum albumin to reduce the nonspecific staining. Sections were washed with PBS and incubated at 4 °C with primary antibodies overnight (monoclonal mouse anti-proliferating cell nuclear antigen clone PC 10, Dako Corporation, Carpinteria CA, Denmark) (Greenwell *et al.*, 1991). Slides were then washed twice in PBS (5min. each). The primary antibodies were then linked with biotinylated goat anti-mouse IgG antibody (Dako, LASB Universal kit) for 35 min at room temperature, washed in two changes of PBS (5 min. each), then sections were incubated for 35 min. with streptavidin-conjugated peroxidase. After washing with PBS, sections were stained with 3, 3'-diaminobenzidine solution (DAB, Sigma) for 10 min., then washed in distilled water and counterstained with Mayer's

hematoxylin. Control samples were prepared by omitting the primary antibodies for PCNA. The reaction was performed at the Faculty of Medicine, Minoufiya University. Analysis for PCNA was done by counting ten randomly photographed high-power fields (x400 magnifications) within seminiferous tubules by a blinded observer. Data were analyzed using IBM SPSS software package version 20.

### *Molecular Study*

#### *Comet Assay*

The comet assay, or single cell gel electrophoresis (SCGE), is a commonly-used technic for detection, analyzing and measuring DNA damage in individual cells. The method of Singh *et al.*, (1988), which involves the unwinding of DNA under alkaline conditions, was used in this study. 0.5 g of crushed samples were transferred to 1 ml ice-cold PBS. This suspension was stirred for 5 min and filtered. Cell suspension (100  $\mu$ l) was mixed with 600  $\mu$ l of low-melting agarose (0.8% in PBS). 100  $\mu$ l of this mixture was spread on pre-coated slides. Immersed coated slides in lyses buffer (0.045 MTBE, pH 8.4, containing 2.5% SDS) for 15 minutes. Slides were placed in electrophoresis chamber containing the same TBE buffer, but devoid of SDS. Conditions of electrophoresis were 2 V/cm for 2 min and 100 mA. Ethidium bromide (20  $\mu$ g/ml) was used for staining at 4 °C. Observation was carried out with samples which still humid, the DNA fragment migration patterns of 100 cells for each treatment or dose level were evaluated with a fluorescence microscope (With excitation filter 420-490nm [issue 510nm]).

The comet tail lengths were measured from the middle of the nucleus to the end of the tail with 40x increase for the count and measure the size of the comet. To visualize DNA damage, observations were made of EtBr-stained DNA using 40x objective of fluorescent microscope. Although any system of image analysis may be suitable for the quantitation of SCGE data, we use a comet 5 image analysis software developed by Kinetic Imaging, Ltd. (Liverpool, UK) linked to a CCD camera to assess the quantitative and qualitative extent of DNA damage in cells by measuring the length of DNA migration and the percentage of migrated DNA.

The comet tail lengths were measured from the middle of the nucleus to the end of the tail with 40x increase for the count and measure the size of the comet. To visualize DNA damage, observations were made of EtBr-stained DNA using 40x objective of fluorescent microscope. Although any system of image analysis may be suitable for the quantitation of SCGE data, we use a comet 5 image analysis software developed by Kinetic Imaging, Ltd. (Liverpool, UK) linked to a CCD camera to assess the quantitative and qualitative extent of DNA damage in cells by measuring the length of DNA migration and the percentage of migrated DNA.

The percentage of fragmented DNA in the comet tail is a direct measure of DNA damage. Finally, the program calculates tail moment. The tail moment was defined by the percentage of DNA in the tail multiplied by the length between the center of the head and tail which was defined by Olive *et al.*, (1990). Generally, 50 to 100 randomly selected cells were analyzed per sample.

#### *Hormonal Assay*

Testosterone levels for control and experimental groups were determined according to the method of Wheeler (1995).

### *Statistical Analysis*

The results were expressed as mean  $\pm$  SE. Data were analyzed by comparing values for different treatment groups with the values for individual controls. Significant differences among different groups were analyzed using Excel 2010 for student t- test,  $p \leq 0.05$  was considered significant.

## **Results**

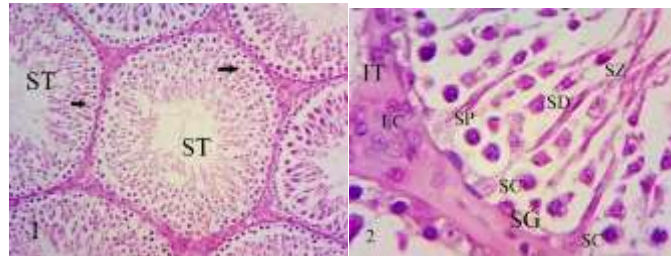
### *Histological results*

#### *Effect of Different Treatments on Cellular Morphology of Testis*

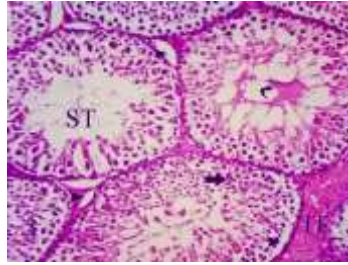
The results of microscopic surveys showed that Hand E staining demonstrated the normal histological structure of testis in animals of the control group (Figs 1, 2). But, the testicular tissue of ZnO-NPs administrated group (1 g/kg/day dose) exhibited disorganized germ cells inside testicular tubules with sloughing of spermatogonia from the basal lamina and edematous lumens and interstitial tissue (Fig 3). In higher magnifications, the toxicity of ZnO-NPs in the testicular tissue appeared clearer where all spermatogenic and Leydig cells were severely damaged together with vacuolization in the interstitial tissue. Leydig cells appeared of low number and irregular shape with degradation in their nuclei and cytoplasm. Other germ cells exhibited signs of apoptosis (Fig 4). The administration of Vit E to experimental rats (100 mg/kg/day dose) exerted non-detectable effect on the histological picture of testis (Fig 5). However, the co-administration of Vit E with ZnO-NPs resulted in a marked activity and regeneration in the testicular tissue. The seminiferous tubules restored their normal shape with increased cellularity and lumens full-packed with sperms (Fig 6). The cells of the spermatogenic series displayed an evident increase in acidophilia and basophilia in their cytoplasm and nuclei respectively, while those of Leydig seemed lively with increased number and prominent nuclei (Fig 7). Those who received ZnO-NPs and left to recover for 21 days disclosed a remarkable repair in the structure of testicular tubules with increased cellularity inside and outside the tubules (Fig 8).

#### *Effect of Different Treatments on Seminiferous Tubule Diameter*

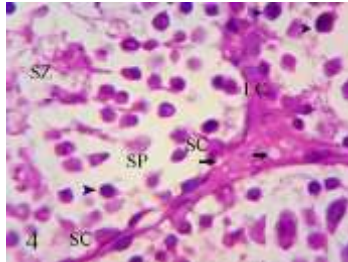
Exposure of experimental rats to ZnO-NPs toxicity either in G2 or in the recovery group (G5) significantly reduced ( $p \leq 0.00005$  and  $p \leq 0.0004$ , respectively) the diameter of the seminiferous tubules as compared to controls (table 1). The onset which reflects a marked decrease in spermatogenesis. However, administration of VE either singly (in G3) or in combination with ZnO-NPs (in G4) significantly-increased the diameter of testicular tubules ( $p \leq 0.002$  and  $p \leq 0.00005$ , respectively) as compared to ZnO group. The matter that referred to an increased activity of spermatogenesis, particularly, in those which co-administered with ZnO-NPs and VE.



**Figs 1, 2:** Sections of testis of control rats (H & E, X400 & X1000 respectively) illustrating the normal histological pattern of seminiferous tubules with well organised spermatogenic cells (arrows) in Fig 1. Fig 2: Magnified portion of a seminiferous tubule showing the different stages of male germ cells.



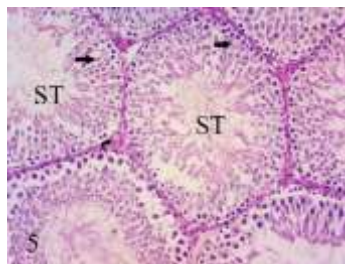
**Fig 3:** Section of testis of ZnO-NPs intoxicated rat (H & E, X400) showing seminiferous tubules (ST) with disorganized spermatogenic cells (arrow), edematous lumen (curved arrow) and detached spermatogonia from the basal lamina (arrow heads) and edematous interstitial tissue (IT).



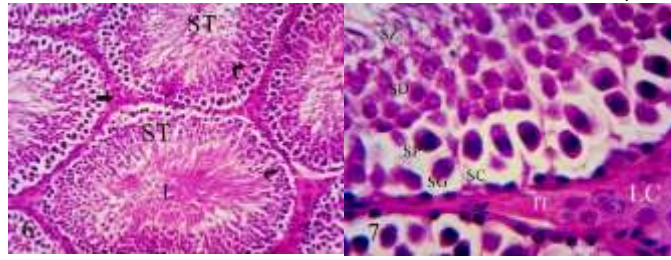
**Fig 4:** Section of testis of ZnO-NPs intoxicated rat (H & E, X1000) exhibiting highly damaged Sertoli cells, spermatocytes, spermatozoa, Leydig cells and vacuolated interstitial tissue (arrows). Leydig cells appeared fewer in number, irregular in shape with degradation of the nucleus and cytoplasm. Other spermatogenic cells are apoptotic (arrowheads).

*Abbreviations*

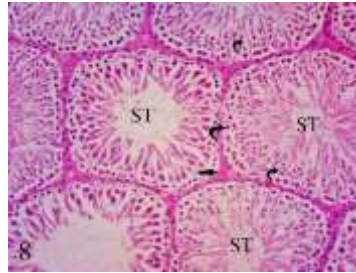ST, seminiferous tubules, SG, spermatogonia, SC, Sertoli cell, SP, spermatocyte, SD, spermatids, SZ, spermatozoa, IT, interstitial tissue and LC, Leydig cells.



**Fig 5:** Section of testis of VE- treated rat (H & E, X400) exhibiting a nearly normal seminiferous tubules with good organized spermatogenic cells (arrows) and interstitial tissue (curved arrow).



**Figs 6, 7:** Sections of testis of ZnO-NPs intoxicated rat treated with VE (H & E, X400 & X1000, respectively) showing ST with normal shapes, increased cellularity (curved arrows) and lumen (L) crowded with spermatozoa and increased number of interstitial cells (straight arrow) in Fig 6. The higher magnification (Fig 7) revealed regenerated spermatogenic cells (SG, SC, SP, SD and SZ) with an increased basophilia and acidophilia in nuclei and cytoplasm (respectively) of all cells. Leydig cells appeared intact with prominent nucleoli.



**Fig 8:** Section of testis of recovery group (H & E, X400) exhibiting reconstructed seminiferous tubules with nearly normal shapes and increased intratubular and intertubular cellularity (curved and straight arrows, respectively).

**Table 1:** Mean diameter of seminiferous tubules of control, treated and recovery groups.

	<b>CONTROL</b>	<b>ZnO</b>	<b>Vit E</b>	<b>ZnO + Vit E</b>	<b>Recovery</b>
Mean diameter	74.6	63.2	76.7	82.5	66.2
Stand dev.	3.7	5.5	3.9	6.6	4.7
T (control) $p \leq$		0.00005	0.3	0.02	0.0004
T (ZnO) $p \leq$			0.002	0.00005	0.3

#### *Effect of Different Treatments on Collagen*

Intoxication of experimental animals with ZnO-NPs displayed a significant increase ( $p \leq 0.0005$ ) in thickness of ECM around the seminiferous tubules as compared to controls. Masson's trichrome stain demonstrated that the increased thickness of the ECM was due to increased synthesis of collagen fibers surrounding the tubules (Fig 9a). The increased thickness of the ECM is indicative to an impaired process of spermatogenesis. The ECM of the other treated groups, which received ZnO + VE, VE only, and ZnO and left to recover recorded a significant decrease ( $p \leq 0.0004$ ,  $p \leq 0.0003$  and  $p \leq 0.006$ , respectively) in collagen deposition as compared to ZnO group to refer to an improvement in spermatogenesis (Figs 9b) (table 2).

#### *Immunohistochemical Results*

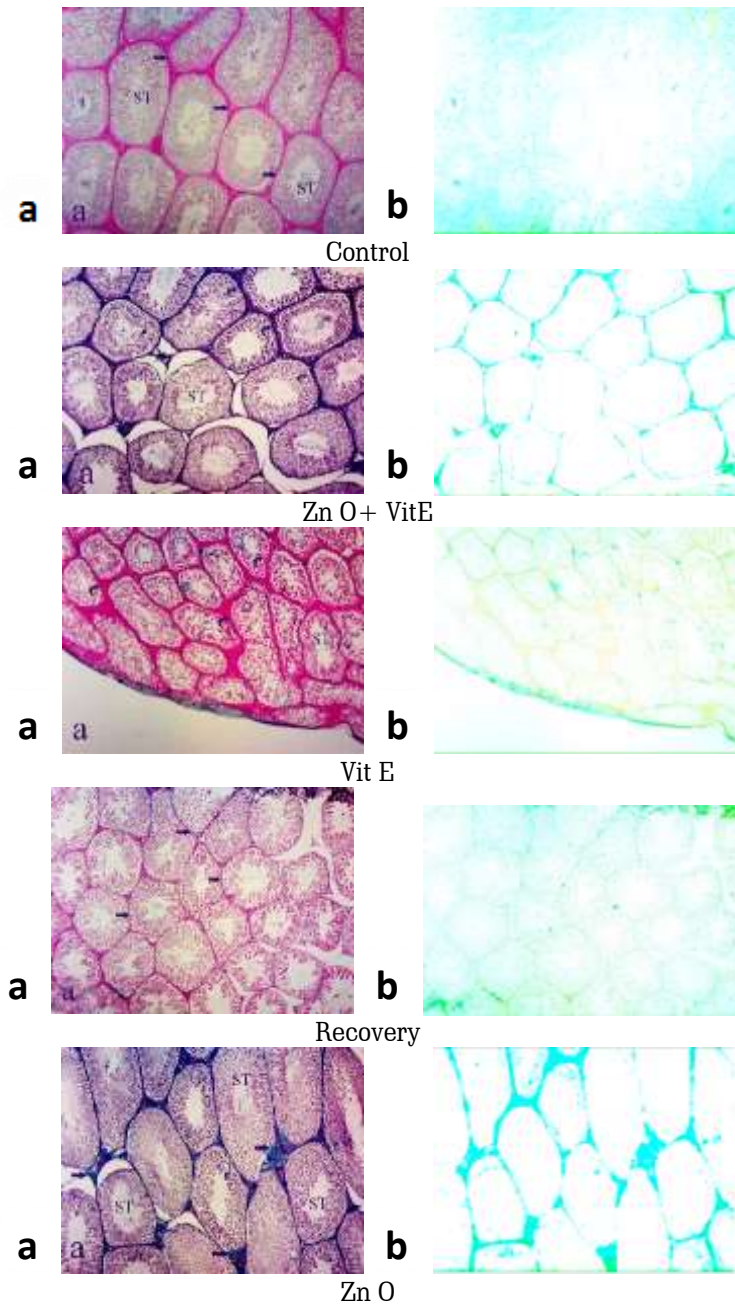
Proliferating Cell Nuclear Antigen (PCNA) was studied as a molecular biomarker for spermatogenesis. Spermatogenic cells from the rat testis were stained with a specific antibody against PCNA. The seminiferous tubules of control animals exhibited a typical PCNA reactivity with an increased number of PCNA-positive cells (Figs 10A). The toxicity of ZnO-NPs induced a partial arrest of spermatogenesis with spermatogonia only being present in most of the seminiferous tubules demonstrated by a weak PCNA expression (Fig 10B). The mean number of PCNA-

positive cells in this group recorded a significant decrease ( $p \leq 0.05$ ) as compared to controls (Fig 14). Vitamin-E-treated rats exhibited a moderate PCNA expression with a non-significant increase ( $p \leq 0.25$ ) in the number of positive cells compared to ZnO- group (Figs 10C). However, the co-administration of Vit E with ZnO-NPs markedly-enhanced PCNA- immunoreactivity in the seminiferous tubules and increased spermatogenesis with  $p \leq 0.09$  approaching a significant value. The matter which reflects an elevated phase of proliferation in comparison to ZnO- group (Figs 10D). While, the recovery group recorded a slight increase in PCNA-immunoreactivity and the number of spermatogenic cells (non-significant  $p \leq 0.35$ ) in comparison to ZnO-group (Figs 10E, 14).

#### *Molecular Results*

The impact of ZnO- NPs administration on testicular DNA of rats is illustrated in table 3 and fig 12, respectively. A pronounced increase in the tail length, DNA % (tail DNA content) and tail-DNA moment was shown in testis of rats intoxicated with ZnO-NPs. Co-administration of VE to ZnO-intoxicated rats significantly protected their testis from DNA damage as indicated by a decrease in tail length, DNA % and tail DNA moment compared with intoxicated rats (Table 3, Fig 12).

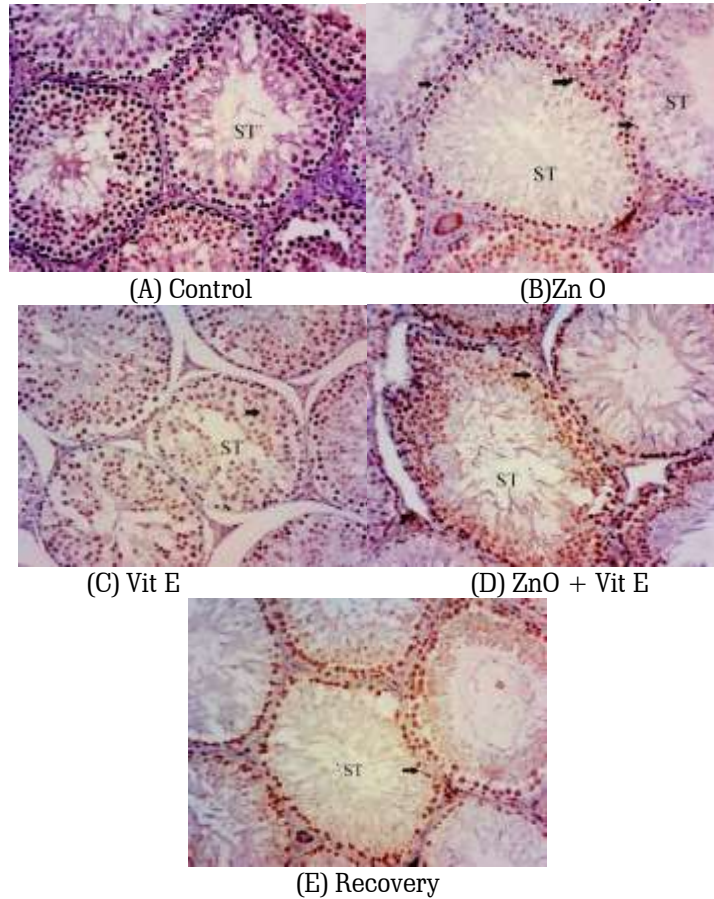




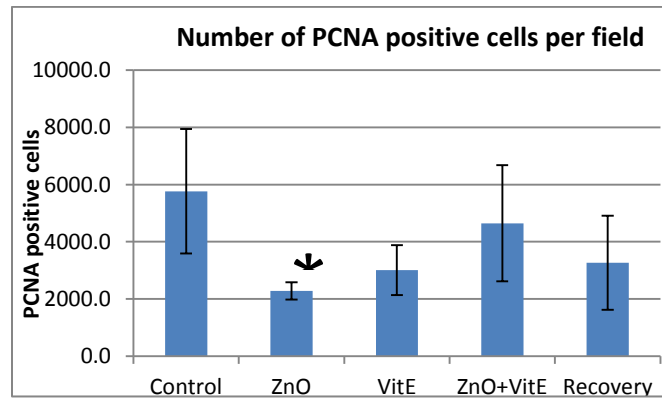
**Fig 9:** (a) Sections in seminiferous tubules (ST) of control, treated and recovery groups, Collagen stained light green in ECM of seminiferous tubules (arrows). (b) Graphical filtration to show collagen deposition in the different groups (Masson's trichrome stain x100)

**Table 2:** Relative area occupied by collagen per field.

	<b>Control</b>	<b>ZnO + VE</b>	<b>VE</b>	<b>recovery</b>	<b>ZnO</b>
mean	1878.676	2156.372	1691.52	2860.752	4215.501
St. Dev	587.5	520.4	297.7	588.3	657.9
T (control) $p \leq$		0.51	0.96	0.08	0.0005
T (ZnO) $p \leq$	0.0005	0.000102	0.0003	0.006	




**Fig 10:** Cross sections of seminiferous tubules (ST) of control, treated and recovery groups (PCNA reaction x 200). (A) Control rats, showing the typical presence of spermatogenic cells with an abundance in the seminiferous tubules. (B) ZnO-NPs-intoxicated rats, showing weaker PCNA-immunoreactivity and a partial arrest of spermatogenesis with spermatogonia only being present (arrows) as compared to control. (C) Vit E-treated rats, a moderate reaction for PCNA was observed in the spermatogenic epithelial cells. (D) ZnO + VE-treated rats, a stronger PCNA-immunoreactivity with an increased number of spermatogenic cells in the seminiferous tubules was observed compared to ZnO-group. (E) Recovery group, a slight elevation in the expression of PCNA was seen (arrow) indicated by the increased PCNA-immunoreactivity as compared to ZnO-group.



**Fig 11:** Mean number of PCNA positive cells per field. Bars: standard deviation. (\*) significantly different from control ( $p \leq 0.05$ ).





**Fig 12:** COMET assay showing the extent of DNA damage in the testicular tissue in ZnO-NPs- intoxicated rats and the effect of vitamin E treatment on the level of DNA damage. (1) Normal control group, (2) group intoxicated with ZnO-NPs, (3) group treated with VE, (4) group intoxicated with ZnO-NPs and co-administered with vitamin E and (5) recovery group, intoxicated with ZnO-NPs and left to recover.

**Table 3:** Values of Comet parameters in control, treated and recovery groups of rats

	TAILED	UNTAILED	TAIL LENGTH	TAIL DNA	TAIL MOMENT
	%	%	$\mu\text{m}$	%	UNIT
(control)	5	95	1.26	1.33	1.68
(ZnO)	14	86	2.58	2.67	6.89
(Vit. E)	6	94	1.33	1.41	1.88
(ZnO +VE)	9	91	2.05	1.81	3.87
(Recov. G)	8	92	2.13	1.77	3.77

#### Change of Testosterone

The mean testosterone concentrations in group which received ZnO-NPs showed significant decrease ( $P \leq 0.0004$ ) compared to control group. While, the combination of vitamin E with ZnO-NPs significantly-increased this value

( $p \leq 0.0004$ ) towards the normal status as compared to ZnO-group. The other studied groups (Vit E and Recovery groups) in their turn recorded significant increase ( $p \leq 0.0004$ ) in testosterone level compared to ZnO-group (table 4).

**Table 2:** Mean testosterone concentration in sera of control, treated and recovered rats.

	Control	ZnO	ZnO + Vit E	Vit E	Recovery
Mean testosterone	0.59	0.02	0.37	0.73	0.56
Stand. deviation	0.06	0.005	0.03	0.03	0.05
T(Control) $p \leq$		<0.0001	<0.0001	0.0001	0.35
T(Zn O) $p \leq$			<0.0001	<0.0001	<0.0001

## Discussion

Exposure to Nano materials becomes unavoidable since these substances constitute a large part of our daily life, accordingly, Nano toxicity is gaining now great attention in recent research work (Filippi *et al.*, 2015). Most researchers focused their studies on the effects of ZnO-NPs on human health, while restricted data were available on the male reproductive system. Testes are the main reproductive organs for male that develop sperms and secrete testosterone in mammals. Exposure of experimental animals to ZnO-NPs in the current study induced apoptosis in the testicular tissue leading to damaged Leydig cells (LCs), Sertoli cells (SCs) and all other spermatogenic cells with intratubular and intertubular hemorrhage, sloughing of germinal epithelia and conspicuous, vacuolization in the interstitial tissue. These criteria may be attributed to the released reactive oxygen species (ROS) due to exposure. These results are in

line with previous studies showing that cytotoxicity and induction of apoptosis in LCs and SCs of testes were verified in neonatal mice by silver NPs (Kumar and Rani, 2013), in newborn male Wistar rats (Shirvani *et al.*, 2014) and in adult mice by ZnO-NPs (Han *et al.*, 2016). Han *et al.* (2016) reported that ZnO NPs have the prospect to induce apoptosis in testicular cells consequent to DNA damage caused by ROS, with possible adverse effects on spermatogenesis and finally, male fertility. According to Bockelheide *et al.* (2000), the presence of vacuoles in the cytoplasm of Sertoli cells and between cell lines of seminiferous tubules is one of the obvious signs of tissue damage indicating direct harm of NPs on these cells. Ahamed *et al.* (2011) reported that ZnO-NPs cytotoxicity is mediated by the generation of free radicals through the induction of lipid peroxidation and ROS-dependent DNA damage by the metabolic pathways of  $P^{53}$ , bax/bcl-2 and caspases. The results of histomorphometric measurements obtained in this study recorded that nanoparticles significantly- decreased the diameter of

seminiferous tubules and conversely increased collagen thickness of the extracellular matrix (ECM) of these tubules. Both of them is related to and confirmed by the other and provides a good indicator to an impaired spermatogenesis due to exposure. These results are strongly consistent with the preceding histological results in this study to approve the harmful impact of these NPs on the male fertility. Our results are consistent with Talebi *et al.* (2013) and Leavy *et al.* (2017). The first authors recorded a significant decrease in height, diameter and maturation of seminiferous epithelia after NPs exposure. The second authors reported that the increased collagen synthesis within the ECM of the seminiferous tubules is of particular interest because an increase in thickness of the ECM has been associated with male infertility (Enders *et al.*, 1995 and Leavy *et al.*, 2017). A correlation between ECM thickness and hypospermatogenesis has been demonstrated: testes from hypospermatogenic men exhibited an increase in thickness of ECM of the seminiferous tubule together with a decrease in diameter of these tubules (Gulkesen *et al.*, 2002). Synthesis of the ECM components such as collagen and laminin was recorded as one of Sertoli cell functions (Skinner *et al.*, 1985). Therefore, they considered the increased collagen synthesis might also be a result of impaired Sertoli cell function. The use of PCNA in the present study was taken as a molecular biomarker to assess spermatogenesis since the latter is a multi-complex cell cycle of rapid proliferating cells ending with formation of sperms. PCNA is a nuclear polypeptide and a cofactor of DNA polymerase delta that is essential for replication, excision and repair (Kanter *et al.*, 2013). Therefore, the current immunohistochemical results recorded that PCNA positive cells were strongly expressed in spermatogonia and early-stage spermatocytes of non-treated control rats. In contrast, the density of PCNA positive testicular germ cells was significantly diminished in ZnO-NPs intoxicated rats, which is an indication of disruption in proliferation and spermatogenesis. The damaging effect of ZnO-NPs on DNA was investigated in the present study using Comet assay. The comet is an accurate and a simple technic for evaluating DNA damage at the level of individual cells (Singh *et al.*, 1988). Apoptotic cell death due to fragmentation lead to increased DNA migration (Tice and Strauss 1995). Using comet to detect DNA damage in the current work indicated that ZnO- NPs intoxication induced testicular DNA damage documented by a significant increase in the tail length, DNA % in the tail and tail-DNA moment in testis of rats. These results cooperate with those of PCNA to confirm the genotoxic effect of ZnO-NPs. Previous studies suggested that ZnO- induced DNA damage may be attributed to oxidative stress and lipid peroxidation (Xiong *et al.*, 2011). The released ROS react directly with DNA, causing damage to both pyrimidine and purine bases as well as the DNA backbone (Martinez *et al.*, 2003). The level of the testicular androgen, testosterone, was assessed in our study as a primary target reflecting the status of the Leydig cells of the interstitial tissue and

concomitantly the testicular function. Results indicated that ZnO-NPs intoxication led to a significant decrease in sera concentrations of testosterone of the exposed animals that may be affect fertility potential of rats. These results are in agreement with those of Ostrowska (2006) who recorded a significant decrease in testosterone levels in animals treated with 40 mg/kg/bw ZnO NPs. Nano ZnO reduces serum testosterone since it reduces cortisol due to the destructive effect of nanoparticles on adrenal glands (Reza *et al.*, 2014). In the present study, vitamin E was used as an antioxidant in co-administration with ZnO-NPs and provided surprising results in optimizing the histological, immunohistochemical, histomorphometric, molecular and biochemical alterations towards the normal picture of control testis. It minimizes the appearance of the histopathological features, increased diameter of ST and decreased the thickness of their ECM to improve spermatogenesis, up-regulated PCNA expression to promote cell cycle progression leading to cellular proliferation improving spermatogenesis, reduced the DNA fragmentation in comet and elevated testosterone level. The protective action of Vit E against ZnO-NPs toxicity induced in rats may attributed to its ability in the inhibition of inflammatory mediators expression. The anti-inflammatory role of vit E is associated with the amelioration of oxidative damage, trapping of reactive nitrogen species (Tahan *et al.*, 2011), as well as down-regulating other inflammatory markers as IL-6 (Lee, 2011). Furthermore, a decrease in oxidative stress by vit E may also be involved in their anti-inflammatory effects (Schaffer and Muller, 2005). The possible role of naturally occurring antioxidants in protection against oxidative DNA damage has been studied, vit E has the ability to reduce the oxidative DNA damage (Makpol *et al.*, 2011). The capacity of vit E to decrease some target organ/cell specific induction of oxidative DNA damage would explain on the basis that vit E easily intercept the increases in ROS generated further away (e.g. by metabolism of xenobiotics in the cytoplasm) before it can diffuse to the nucleus and damage the DNA (Cadenas *et al.*, 1997).

## Conclusion

These results demonstrated that ZnO NPs have the potential to induce apoptosis in testicular cells via DNA damage caused by ROS with possible adverse consequences for spermatogenesis and male fertility. This suggests that widespread application of ZnO NPs should be carefully assessed and precautionary measures must be planned out to prevent human exposures to such NPs. Also, vit E supplementation as prophylactic agent may be beneficial against inflammatory responses induced testicular injury and oxidative DNA damage caused by toxic effect of ZnO Nano-particles.

## References

- Ahamed M., Akhtar M.J., and Raja M., *et al.* ZnO Nano-induced apoptosis in human alveolar adenocarcinoma cells via p53, surviving and bax/bcl-2 pathways: role of oxidative stress. *Nano medicine*. 2011, 7 (6): 904–913.
- Bockelheide K., Fleming S.L., Johnson K.J., Patel S.R., Schoenfeld H.A. Role of sertoli cells in injury associated testicular germ cell apoptosis. *Exp Biol Med*. 2000, 25 (2): 105-115.
- Cadenas S, Barja1 G, Poulsen He, Loft S. Oxidative DNA damage estimated by oxo8dG in the liver of guinea-pigs supplemented with graded dietary doses of ascorbic acid and  $\alpha$ -tocopherol. *Carcinogenesis* 1997; 18: 2373-2377.
- Enders G.C., *et al.* Developmental changes in seminiferous tubule extracellular matrix components of the mouse testis: alpha 3 (IV) collagen chain expressed at the initiation of spermatogenesis. *Biol Reprod*. 1995, 53: 1489–99 (1995).
- Filippi C., Pryde A., Cowan P., Lee T., Hayes P., Donaldson K., Plevris J., Stone V. Toxicology of ZnO and TiO<sub>2</sub> nanoparticles on hepatocytes: impact on metabolism and bioenergetics. *Nano toxicology*. 2015, 9: 126–134
- Greenwell A., Foley J.F., Maronpot R.R. 1991. An enhancement method for immunohistochemical staining of proliferating cell nuclear antigen in archival rodent tissues. *Cancer Letters*. 1991, 59: 251-256.
- Gulkesen K.H., Erdođru T., Sargin C.F., Karpuzođlu G. Expression of extracellular matrix proteins and vimentin in testes of azoospermic man: an immunohistochemical and morphometric study. *Asian J Androl*. 2002, 4: 55–60.
- Guo D., Bia H., Wang D., Wu Q. Zinc oxide nanoparticles decrease the expression and activity of plasma membrane calcium ATPase, disrupt the intracellular calcium homeostasis in rat retinal ganglion cells, *Int J Bio chem Cell B*. 2013, 45, (8): 1849– 1859
- Han D., Tian Y., Zhang T., Ren G., Yang Z. Nano-ZnO damages spatial cognition capability via over-enhanced long-term potentiation in hippocampus of Wistar rats, *Int. J. Nano medicine*. 2011, (6): 1453–1461.
- Han Z., Ge Q.Y.W., Liu Z., Gurunathan S., Felici M.D., Shen W., Zhang X.F. Cytotoxic effects of ZnO nanoparticles on mouse testicular cells. *International Journal of Nano medicine* 2016, 11: 5187–5203.
- Kanter M., Aktas C., Erboga M. Curcumin attenuates testicular damage, apoptotic germ cell death, and oxidative stress in streptozotocin-induced diabetic rats. *Mol Nutr Food Res*. 2013, 57: 1578–1585.
- Kumar H., Rani R. Development of biosensors for the detection of biological warfare agents: its issues and challenges. *Sci Prog*. 2013, 96 (Pt. 3): 294–308.
- Leavy M., Trottmann M., Liedl B., Reese S., Stief C., Freitag B., Baugh J., Spagnoli GKölle S. Effects of elevated  $\beta$ -estradiol levels on the functional morphology of the testis – new insights. *Scientific Reports*. 2017, 7: DOI: 10.1038/srep39934
- Lee Y., Kim M., Choi K., Kim J., Bae W., Kim S., Sohn C. Relationship between inflammation biomarkers, antioxidant vitamins, and bone mineral density in patients with metabolic syndrome. *Nutr Res Pract* 2011, 5: 150-156.
- Levison D.A., Bancroft J.D., Stevens A. *Theory and Practice of Histological Techniques*. 1996, (4th edn) Churchill Livingstone, UK, 766.
- Makpol S, Durani Lw, Chua Kh, Yusof Yam, Ngah Wzw. Tocotrienol-rich fraction prevents cell cycle arrest and elongates telomere length in senescent human diploid fibroblasts. *J Biomed Biotechnol* 2011; 2011: 506171.
- Martinez G.R., Loureiro A.P., Marques S.A., Miyamoto S., Yamaguchi L.F., Onuk J., Almeida E.A., Garcia C.C., Barbosa L.F., Medeiros M.H. and Di Mascio. Oxidative and alkylating damage in DNA. *Mutat Res* 2003, 544: 115-127.
- Matter F.E. Graphical filtration of Masson's trichrome – stained sections to demonstrate collagen. 2017, Unpublished.
- Mironava T., Hadji L. Argyrou M., Simon M., Jurukovski V., Rafailovich M.H. Gold nanoparticles cellular toxicity and recovery: Effect of size, concentration and exposure time. *Nano toxicol*. 2010, 4: 120-137.
- Namvar F., Rahman H.S., Mohamad R., *et al.* Cytotoxic effects of biosynthesized zinc oxin nanoparticles on murine cell lines. *Evid Based Complement Alternat Med*. 2015, 2015: 593014.
- Olive P.L., Banath J.P., Durand RE. Heterogeneity in radiation induced DNA damage and repair in tumor and normal cells using the "Comet" assay. *Radiat Res*. 1990, 122: 86-94.
- Ostrowska J.G. Effect of dietary fat on androgen secretion and metabolism. *Reprod Biol*. 2006, (6): 13-21.
- Pearse A. *Histochemistry, Theoretical and Applied*. 1977, 3<sup>rd</sup>. Ed., 1: Churchill Livingstone, London.
- Reza E.H., Kobra S., Leila S., Vahid Y., Esmail A. Investigation of the zinc oxide nanoparticles effect on testosterone, cholesterol and cortisol in rats. *Research Journal of Recent Sciences*. 2014, 3 (4): 14-19.
- Rikans L.E., Moore D.R., Snowden C.D. (1991): Sex-dependent differences in the effects of aging on antioxidant defense mechanisms of rat liver. *Biochim Biophys Acta*. 1991, 1074: 195– 200.
- Saptarshi S.R., Feltis B.N., Wright P.F., Lopata AL. Investigating the immunomodulatory nature of zinc oxide nanoparticles at sub-cytotoxic levels in vitro and after intranasal instillation in vivo. *J Nano bio technology*. 2015, 13:6
- Schaffer S., Muller We, Eckert Gp. Tocotrienols: constitutional effects in aging and disease. *J Nutr* 2005, 135: 151-154.
- Sharma M., Gupta Y.K. Effect of alpha lipoic acid on intracerebro-ventricular streptozotocin model of

- cognitive impairment in rats. *Eur Neuro psychopharmacol.* 2003, 13: 241-247
- Shirvani H., Noori A., Mashayekh A.M. The effect of ZnO nanoparticles on the growth and puberty of newborn male Wistar rats. *International Journal of Basic Sciences & Applied Research.* 2014, 3 (SP): 180-185.
- Singh N.P., McCoy M.T., Tice R.R., Schneider E.L. A simple technique for quantitation of low levels of DNA damage in individual cells. *Exp Cell Res.* 1988, 175 (1): 184-191.
- Skinner, M.K., Tung, P.S. & Fritz, I.B. Cooperativity between Sertoli cells and testicular peritubular cells in the production and deposition of extracellular matrix components. *J. Cell Biol.* 100, 1941-7 (1985)
- Tahan G., Aytac E., Aytekin H., Gunduz F., Dogusoy G., Aydin S., Tahan V., Uzun H. Vitamin E has a dual effect of anti-inflammatory and antioxidant activities in acetic acid-induced ulcerative colitis in rats. *Can J Surg* 2014, 54: 333-338.
- Talebi A.R., Khorsandi L., Moridian M. The effect of zinc oxide nanoparticles on mouse spermatogenesis. *J Assist Reprod Genet.* 2013, 30 (9): 1203-1209.
- Tice R.R., Strauss G.H.S. The single cell gel electrophoresis comet assay - a potential tool for detecting radiation-induced DNA damage in humans. *Stem Cells.* 1995, 13 (Suppl 1): 207-214.
- Wang B., W.Y., Feng *et al.* Acute toxicological impact of Nano-and sub micro-scaled zinc oxide powder on healthy adult mice. *J Nano Particl Res* 2008, 10: 263-276.
- Wheeler, M. The determination of bio-available testosterone. *Ann Clin Bio chem.* 1995, 32: 345-357.
- Xiong D., Fang T., Yu L., Sima X. and Zhu W. Effects of Nano-scale TiO<sub>2</sub>, ZnO and their bulk counterparts on zebra fish: Acute toxicity, oxidative stress and oxidative damage. *Sci Total Environ.* 2011, 409 (8): 1444-1452.
- Yousefi Babadi V., Amraeai E., Salehh H., Sadeghi L., Najafi L., Fazilati M. Evaluation of Iron Oxide nanoparticles effects on tissue and Enzymes of Thyroid in Rats. *Int Res J Biological Sci.* 2013, 2: 67-69.