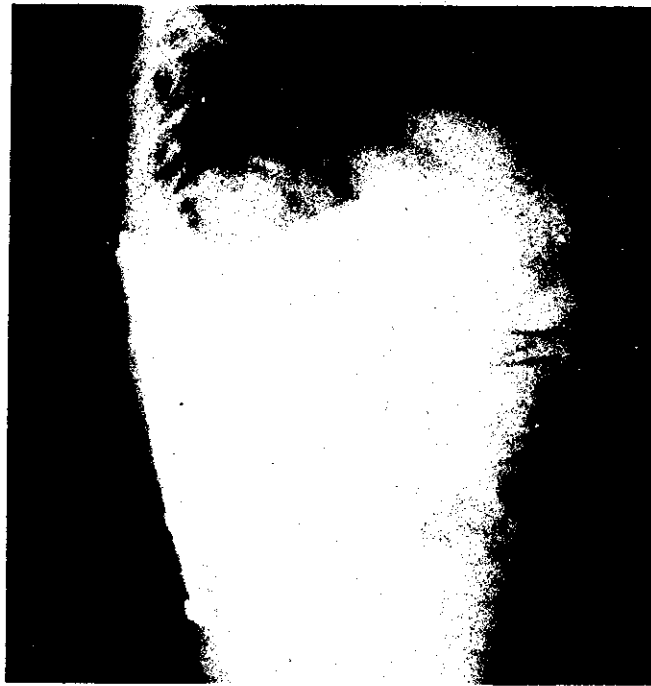

(A)

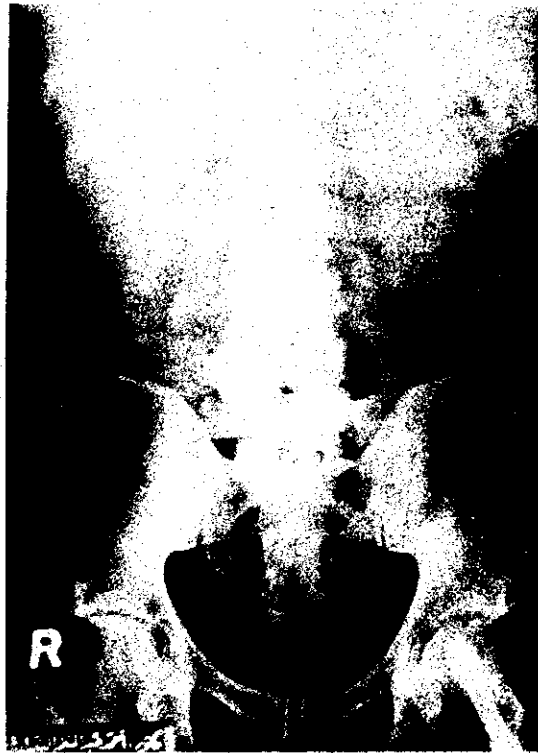

(B)



Fig. (43) A and B: Note the broken screws and the unmoulded construct.

(A)



(B)

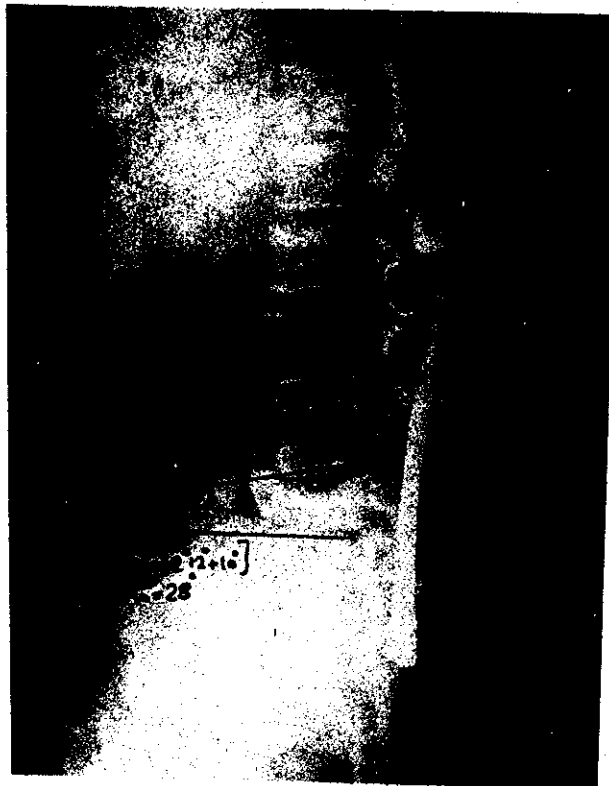

Fig. (44) A and B: Note the collapse of L4 even with the use of distraction rods.



Fig. (45) Case No.() Complete paraplegia with a large trochanteric bed sore in a case treated conservatively.

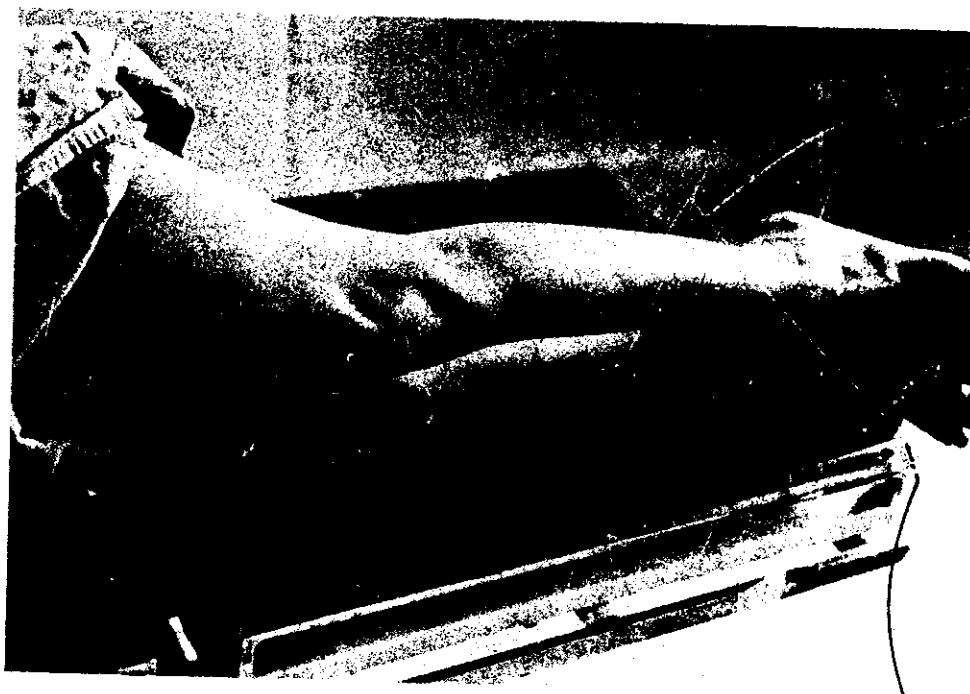

Fig. (46): Case No. () Spastic flexion attitude of lower limbs in patient with incomplete neural deficit.



Fig. (47) Case No () A completely paraplegic female patient with multipule bed sores and a urinary catheter.

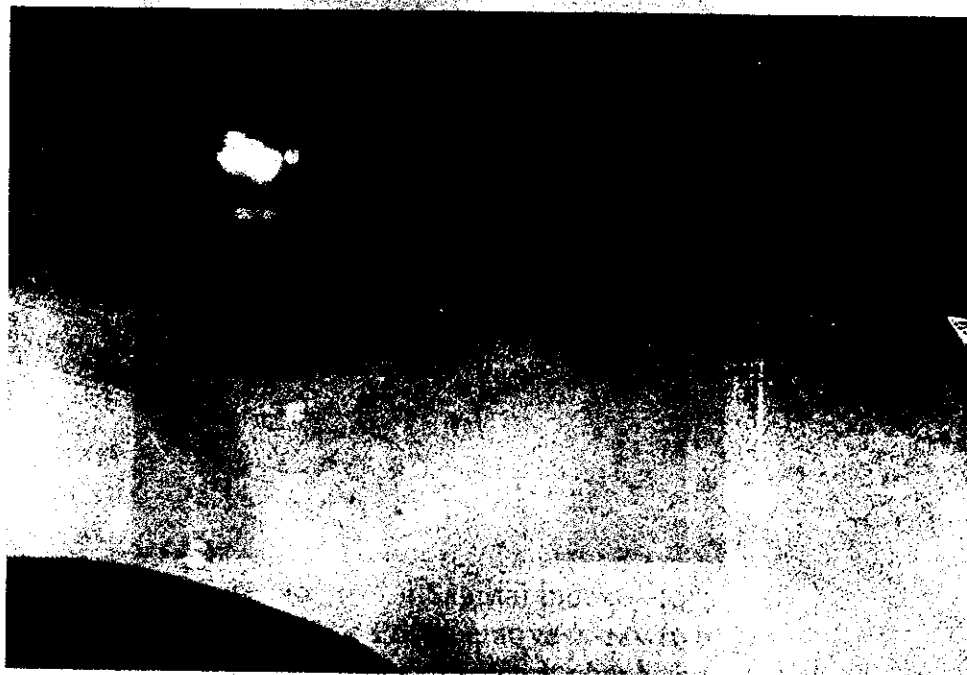


Fig. (48) Case No. () Note the severe thoracolumbar kyphosis and the compensatory hyperlordosis of the lumbar spine.




Fig (51) Notched spinal plate with missing of level above and level below.

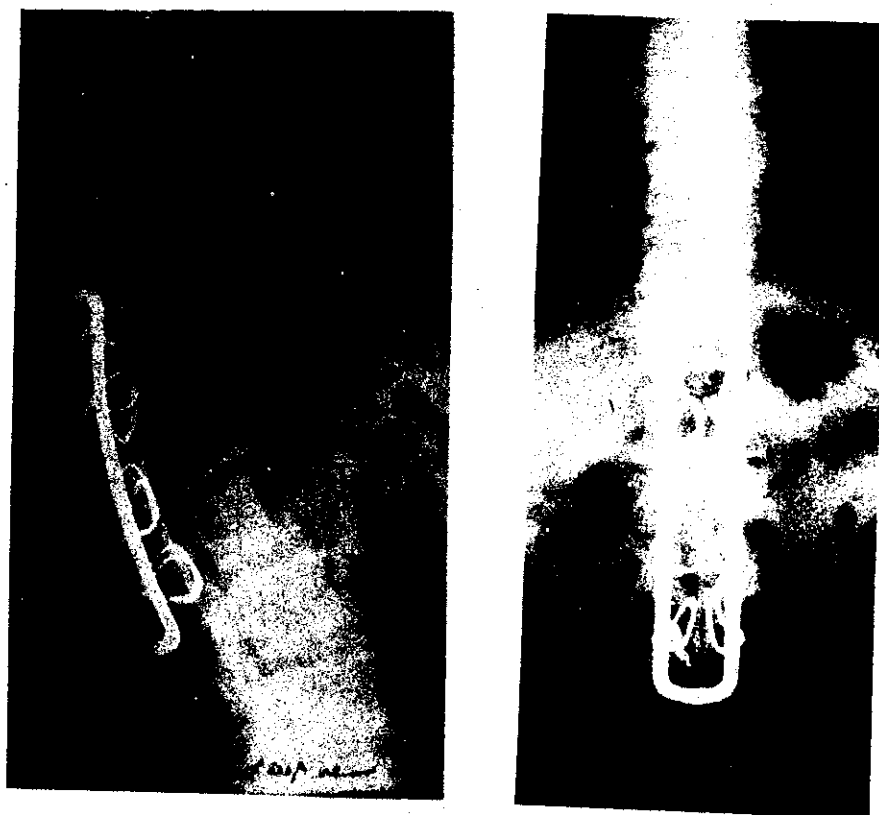


Fig (52) Hartshill rectangle with severe sagittal index and posterior displacement.

(A)



(B)



Fig. (53) A and B: An example of screws malposition.