

Introduction

An intestinal fistula is an abnormal communication between two epithelialized surfaces. Intestinal fistula may be formed between intestine and adjacent viscous (entero-enteral) or skin (entero-cutaneous) . They may be congenital but are usually acquired. Primary or type I fistula develop as a result of an underlying disease affecting the gut wall. Secondary or type II fistula occur after injury to normal gut .This classification has practical implication for surgical management of intestinal fistula (*slade and Scott , 2005*).

In an era when mortality from pancreatico-duodenectomy is less than 3% the mortality from entero-cuetaneous fistula remains 10-30 % due to often present complications. The fistulae commonly develop as post operative complication of bowel surgery though in 15% to 20% of cases fistulae occur spontaneously. Spontaneous fistula may arise in patients with inflammatory bowel disease (I.B.D) ,radiation enteritis, diverticular disease, and perforated duodenal ulcers (*Evenson and Fischer, 2006*).

Enteroenteric or enterocolic fistulae may remain unrecognized if small length of bowel is by passed .however ,if longer lengths of bowel are by passed there will be significant metabolic and nutritional disturbances .Enterovesical fistula may present as recurrent urinary tract infection (U.T.I) , pneumaturia, or fecaluria. External fistulae are usually picked up early in the clinical course. The typical clinical presentation includes febrile post operative course with an erythematous wound, that begins to leak purulent material and finally enteric contents .

The seriousness of an external fistula depends on two factors. Its anatomic location and upon the volume of output it produces. Generally the more proximal a bowel fistula, the larger the amount of output and subsequently the more severe the electrolyte disturbances and malabsorption produces (*Berry and fischer,1996*).

Enterocutaneous fistulae are common postoperative entity ,causing serious complications such as sepsis ,malnutrition, electrolyte and fluid abnormalities ,skin excoriation, and psychological problems. So sepsis coupled with malnutrition is the leading cause of death (*Hamm et al ; 2007*).

In general principles of gastrointestinal (G.I) fistula management are divided into three phases of care ; diagnosis and recognition, stabilization and investigation, and treatment and definitive care (*Clarence et al ;1996*).

Stabilization initially concentrate on correction of fluid and electrolyte imbalance ,drainage of collection ,treatment of sepsis and control of fistula output. The routine use of somatostatin infusion and somatostatin analogues remains controversial. Malnutrition is common, and adequate nutrition provision is essential enteral when possible, although Parenteral nutrition is often required for high output small bowel fistulae (*Liroyd et al ; 2006*).

This is followed by investigation phase despite the fact that barium radiology is widely considered the method of choice in detection of internal fistula ,accuracy was found for U.S and C.T .Endoscopy is done if indicated. Hydrogen peroxide enhanced U.S fistulography could be considered the diagnostic procedure of choice in crohn's disease (C.D) associated entero-coetaneous fistula (*Maconi et al ; 1999*).

The presenting clinical picture influences the surgeon's decision . The surgeon may operate upon the patient early to ensure adequate

drainage of fistula or to perform an ancillary procedure such as feeding jejunostomy or diverting colostomy .Conversely the surgeon may decide to wait ,with expectation that the fistula will eventually close spontaneously with supportive treatment. Thus understanding factors that influence the out come is important (*Gonzalez and Moreno , 2002*).

Aim of the work

Intestinal fistula is one of the most sophisticated and confusing issues that face the surgeons. The aim of this essay is to define this issue with its causes, how to avoid it, discuss its morbid complications and shows the best ways to evaluate, investigate, and manage.

CLASSIFICATION OF INTESTINAL FISTULA

Anatomical classification:

1-according to their communication:

a- Internal fistulae

Exist between intestine and any other hollow viscus . They can be further divided into 2types ; intestinal and extraintestinal . The former refer to a gut to gut connection and may consist of any combination of stomach, small bowel , and colon . The other one imply communication of intestine with another organ system as cosidered below (*Class , 1999*).

Genito-urinary tract ; is a communication between the G.I and genitourinary tract represents a major subset of extraintestinal fistulae . The bladder and vagina are most often affected. But involvement of the upper collecting system , urethra , or uterus is occasionally seen (*Ono et al ; 1995*).

Biliary tract ; cholecystoduodenal fistulae are the most common type , followed by cholecystocolic and choledochoduodenal fistulae (*Yamashita et al ;1997*).

Vascular system ; enteric fistulae involving the vascular system, whether arterial or venous , are potentially lethal and often require urgent correction .The aorta lies in proximity with the gastrointestinal tract (G.I.T) for much of its thoracic and abdominal course . Aortoenteric fistulae , therefore , can potentially involve the gut anywhere from esophagus to the colon . The duodenum participates in the majority of aortoenteric fistulae , owing to the proximity between its third portion and the underlying abdominal aorta. The majority of cases occur in the presence of aortic anurysm disease, either as primary event or a scondary

complication following surgical repair . Enterovenous and colovenous fistulae ; are rare but potentially lethal (most common duodenocaval fistulae due to peptic ulcer disease (*Lee et al ; 2001*)).

Respiratory tract ; fistulae that communicate between the respiratory tract and the intra abdominal gut (gastrobronchial , enterobronchial , and colobronchial fistulae) are rare but may result from a penetrating subphrenic abscess or postsurgical complication . Likewise; gastropleural and colopleural fistulae are also rare (*Baxter et al ; 1998*).

Other fistulae ; less common sites for extraintestinal fistulae include the pericardium , pancreas and skeletal system . Fistula formation between the pericardial space and the esophagus or stomach should be considered in the setting of non traumatic spontaneous pneumopericardium . Most gastropericardial fistulae result from benign penetrating gastric ulcers in stable patients . Fistulae complicating debridement for severe necrotizing pancreatitis are most often enterocutaneous and/or pancreatico-cutaneous but internal pancreatico-enteric communication is demonstrated on rare occasions , fistulae may also form from spontaneous rupture of a pseudo cyst into the stomach, colon , or duodenum . Rare acquired GI fistulae with the skeletal system include colonic communication with the hip (colocoxal) and bowel communication with the spine (enterospinal and colospinal) (*Wang et al ; 1998*).

b- External fistulae (entero-cutaneous):

Occur when hollow viscus discharges to the body surface (*Sloan et al ; 2002*).

c- Mixed fistulae:

Which is a variety of more complex fistulae involves both internal and external communication , often through an abscess cavity (*Hollington et al ; 2004*).

2-According to their tract:

a-Simple fistula :

With a short direct communication between small intestine . It does not involve abscess or other organs (*Foster and Lefor , 2001*).

The simple fistula has a much greater chance of healing spontaneously provided that, there is no distal obstruction (*Met calf , 1999*) .

b-complex fistula :

With one or more tracts that are tortuous and sometimes associated with an intervening abscess cavity half-way along the tract (*Russell et al ; 2000*).

They are classified into 2 types ; type 1, which is associated with abscess formation and involvement of multiple organs . Type 2 , opens into the base of disrupted wound bed and are commonly associated with surgical wound secondary to infection or as a complication from radiation therapy (*Sloan et al ;2002*) .

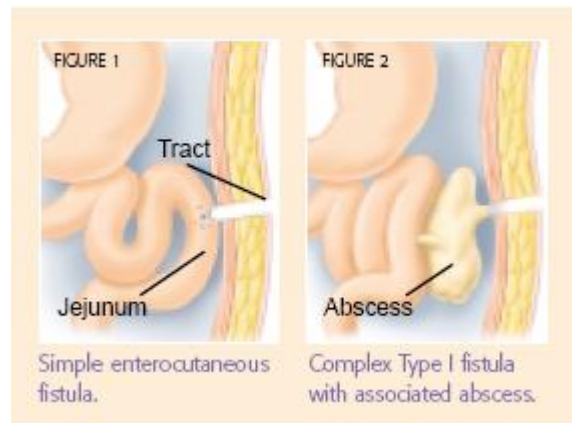


Fig. (1) Classification of fistula according to their tract . Fig (1:1) Simple fistula . Fig (1:2) complex fistula (*Sloan et al ; 2002*).

3-According to laterality :

a-Lateral fistula :

Which arise from the side of a hollow viscus .

b-End fistula :

Those arising from the whole circumference of involved bowel and when there is no further continuity of the GIT (*Lawrence and Doherty 2003*).

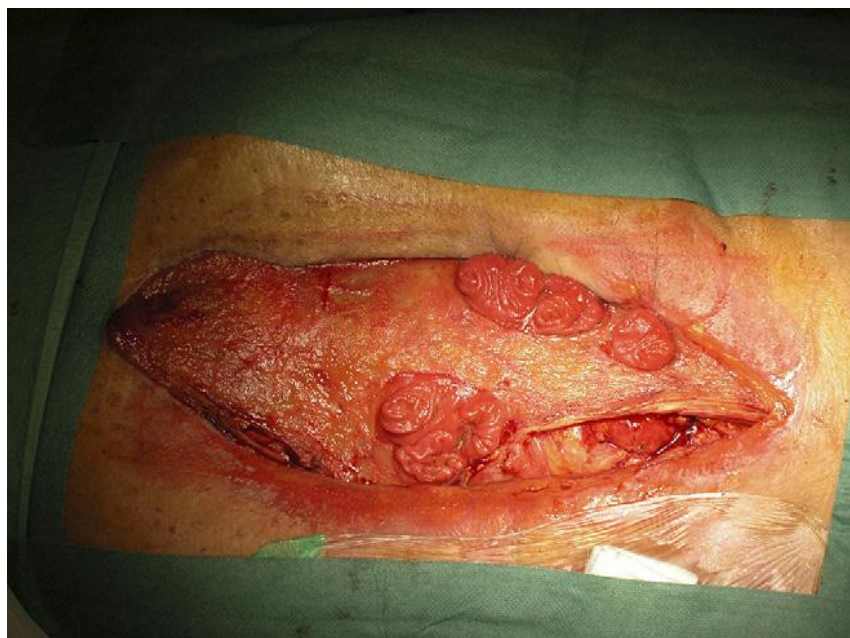


Fig. (2) A case of multiple and wide entero-cutaneous fistulae with total discontinuity of bowel ends “end fistulae” , associated with a large dehiscd abdominal wound (*Dionigi et al ; 2008*).

4-According to level :

a-Proximal fistula .

b-Distal fistula .

Generally, the more proximal the fistula , the larger the amount of output , subsequently , the more severe the complications (*Sakr , 1998*) .

5-According to organ involved :

a-Favorable:

Esophageal , duodenal stump , pancreatic , biliary , jejunal , and colonic .

b-Unfavorable:

Gastric , lateral duodenal , and ileal (*Sakr ,1998*) .

Physiological classification:

According to output volume (for external fistulae) :

a-High output fistulae(HOP) ; are of a daily discharge of enteric contents of > 500ml or pancreatic contents > 200ml .

b-Low output fistulae(LOF) ; < 500ml of enteric contents/day (*Blooma , 2002*).

Other classification :

1-Low output ; < 200ml/day.

2-Moderate output ; 200-500ml/day.

3-High output ; > 500ml/day (*Berryand Fischer, 1996*).

Classification according to the condition of the gut wall

a-Primary type 1 fistula :

That result from underlying disease affecting the gut wall .

b-Secondary type 2 fistula :

That occur after injury to normal gut .

Fistula classification and management

Type of fistula	Example	Classification	Management
Congenital	Tracheo –oeso-phageal fistula	primary	Resection
Inflammatory	C.D.	primary	Resection
	Diverticular disease	primary	Resection
	Pepticulceration	primary	Resection
	Pancreatitis	primary	Conservative/surgical drainage
Neoplastic	Colon cancer	primary	Resection
	Ovarian cancer	primary	Resection
	Small bowel malignancy	primary	Resection
Trauma	Surgery	secondary	Conservative/surgical drainage
	Radiation	primary	Resection
	Penetrating injury	secondary	Conservative/surgical drainage
Infection	Tuberculosis	primary	Anti T.B treatment / resection
	Actinomycoses	primary	Penicillin

Table (1) Classification of intestinal fistula (*Slade and Scott , 2005*) .

This classification has practical implication for surgical management of intestinal fistula . As general rule , type I fistula require surgical resection of the diseased segment .Where as type II fistulae have the potential to close spontaneously with conservative management (*Slade and Scott , 2005*).

Aetiological classification :

1 - Congenital fistula:

Developmental errors may result in both external and internal fistulae , best known examples of the latter are tracheo-esophageal and rectovaginal fistulae (*El Bahar , 1988*).The best example of the former is umbilical fistula . Despite the relatively common occurrence of Meckel's diverticulum , patent vitello-intestinal duct with fistula formation is rare , occurring once in every 15000 births associated with distal intestinal obstruction , such as an imperforate anus (*Burnand and Young , 2004*).

Although it usually presents in childhood as faecal discharge at the time the umbilical cord sloughs , it may not become apparent until adult life , when distal obstruction occurs as colonic carcinoma (*Ruben et al , 2008*).

2 - Acquired fistulae :

A - Inflammatory fistulae :

Inflammation , though the major cause of internal fistula , is rarely the cause of an external fistula without prior surgical interference (*Foster and Lefor , 2001*).

Crohn's disease (C.D.) ; is one of the most important inflammatory causes of fistulae . Approximately 30% of patients of C.D. will develop fistulae , 15% of these fistulae will be external fistulae .

Ileocolic and enterovesical fistulae are the most common types (*Newbould , 2002*).

Crohn's disease is characterized by full thickness granulomatous inflammation that is breached by a fissuring ulcer , leading to abscess breaks through the skin or into an adjacent viscus . The terminal ileum is commonly affected in C.D. , so presentation is often with mass in the right iliac fossa (*Slade and Scott , 2005*).

Fistula formation less common in ulcerative colitis which , unlike C.D. , is not a transmural process . Rectovaginal followed by rectovesical fistula is the most frequent spontaneous GI fistula that develop in ulcerative colitis (*Triantafillidis et al ; 1999*).

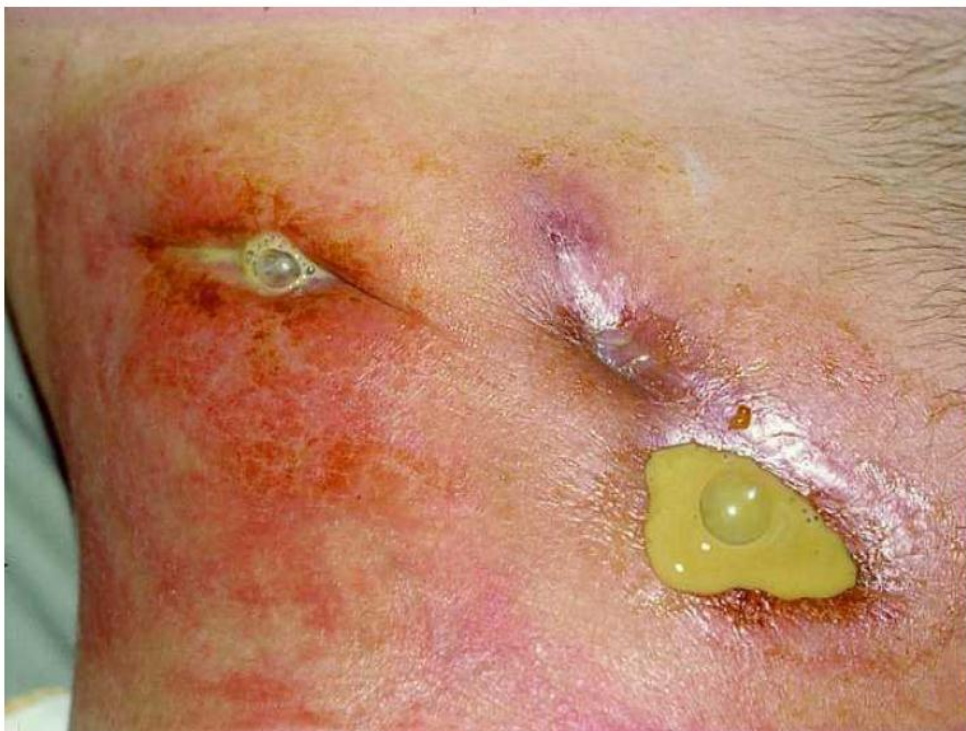

Fig. (3) Spontaneous fistulae occur secondary to C.D. (*Burnand and Young , 2004*)

Crohn's peri-anal fistulae; 70% of patients with C.D have peri-anal symptoms. Fistulae tend to be multiple, with more oedema and may be less painful. Treatment is more conservative as surgical wounds tend to be slow to heal and fistulae tend to be complex (*Shou et al ; 2001*).

Diverticular disease of the colon ; fistula can result if a phlegmon or diverticular abscess extends or ruptures into adjacent organ , colovesical and colovaginal fistulae are commonly encountered . Coloenteric , colouterine , coloureteric , and colocutaneous are much less common (*Branagan and senapati , 2008*).

Another relatively common finding in diverticulitis is a fistulous tract that parallels the colonic lumen , representing localized form of colocolic fistula that has been termed " double tracking" (*Stollman and Raskin , 1999*).

Enterocolic fistulae in C.D. are usually due to primary small bowel disease , whereas the opposite is true for colonic diverticulitis (*Stollman and Raskin , 1999*).

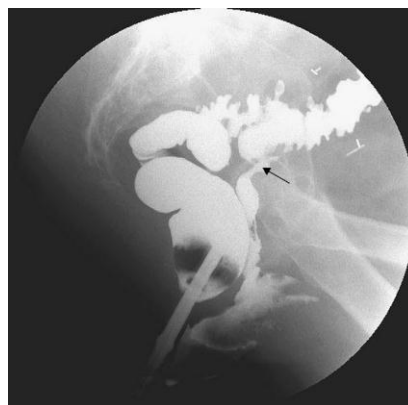


Fig. (4) Fluoroscopy showing a colovaginal fistula . Contrast fills the rectum and sigmoid colon . Extensive sigmoid diverticular disease is present . The arrow marks the site at which contrast delineates a fistula from the sigmoid colon into the vagina (*Branagan and senapati , 2008*).

Necrotizing pancreatitis ; severe type can cause GI fistulation by 2 distinct mechanisms:

a- Proximal pancreatic duct stricturing leading to destruction of the distal duct can result in a pancreatic fistula . Typically, a pseudocyst collection drained percutaneously produces a pancreaticocutaneous fistula.

b- postoperative small bowel fistula ; may result from the management of necrotizing pancreatitis , these fistulae develop as the result of surgical trauma to small bowel loops following repeated laparotomy for necrosectomy (*Chintapatla and Scott ; 2003*) .

Peptic ulceration ; Inadequate gastrectomy for peptic ulceration can lead to recurrent peptic ulceration in the jejunal aspect of the gastrojejunostomy . In some patients , it can progress into fistula formation involving the transverse colon at this site" gastro-jejuno-colic fistula" (*Slade and Scott , 2005*).

Other causes ; atypical infection that reported , T.B , histoplasmosis , actinomycosis , xanthogranulomatous pyelonephritis , amebiasis , echinococcosis , and lymphogranuloma venerum (*Locasto et al ;1997*).

B- Traumatic fistula :

penetrating trauma of the abdomen as by knife or bullets and closed abdominal injury (blunt trauma) may lead to injury of the gut , vascular injury , ischemic problems , or abscess formation . All of which can lead to fistula formation (*Falconi and pederzoli , 2001*).

Usually fistula developed due to the injuries which are difficult to diagnose and remain undetected for a long period and the usual

mechanism is formation of retroperitoneal abscess which opens either into viscus or if drained forms an external fistula (*Kaur et al ; 2004*).

Ingested foreign bodies can lead to fistula formation , through perforating the gut wall and abscess formation at the site of perforation with consequent internal and external fistula formation . Such perforations are more likely to occur in areas where the bowel is already diseased (*Falconi and Pederzoli , 2001*).

C- Neoplastic fistula :

Colorectal cancers may fistulate into any adjacent viscus, producing urinary, enteral, vaginal or cutaneous fistulae (*Slade and Scott, 2005*).

It is not usual for the neoplasm to progress so far in present days as it is almost always diagnosed and resected before this stage (*Chang et al;2000*).

D- Iatrogenic fistulae :

-Intentional fistulae :

Refers to stomas created by surgeon in different surgical circumstances as colostomy , jejunostomy , or ileostomy . It may be transient or permanent (*Gonzalez and Moreno , 2002*) .

- Obstetric fistulae :

Occurs commonly in developing countries related to obstetric complications. The most common type is acquired rectovaginal fistula (*Foster and Lefor , 2001*).

- Post irradiation fistulae :

Irradiation can cause damage to the gut in form of radiation enteritis , fibrosis , radiation necrosis , and fistula formation (*Chintamani et al ; 2003*).

The type of fistula encountered in irradiated bowel is determined by position of the original lesion requiring radiotherapy . Thus , most fistulae are rectovaginal or colovesical following the treatment of genito-urinary malignancy (*Chamberlain et al ; 1998*).

A previous pelvic surgery makes the gut especially the loops of small intestine extra-vulnerable for the development of both external and internal fistulae especially the operations that done for carcinoma in the ovary, cervix , and rectum . This is due to the adhesions that will develop with the pelvic wall (*Chintamani et al ; 2003*).

The presentation may be acute , subacute , chronic (*Chamberlin et al ; 1998*).

Furthermore , bowel resection and anastmosis in previously irradiated tissue increases the risk of anastomotic failure and of fistula formation (*Falconi and Pederzoli , 2001*).

- Post-operative fistulae :

External fistula most often develops in emergent surgical procedures in which the patient has had inadequate bowel preparation (*Chang et al ; 2000*).

Factors responsible for development of post-operative fistulae:

1-systemic factors :

Advanced age , high total billirubin , low creatinine clearance , shock during operation , long operation time , and high intra-operative

blood loss are main factors . There are others suggested although not proved including ; malnutrition , immunocompromised state , infection , bacterial peritonitis , renal insufficiency , hepatic cirrhosis , hypoproteinaemia ,and D.M (*Yeh et al ; 1999*).

2-Local factors :

a- Technical factors :

Improper suturing technique , placement of drain in close proximity to anastomotic line or unrecognized injury in the small bowel (*Memon and Siddiqui ; 2004*).

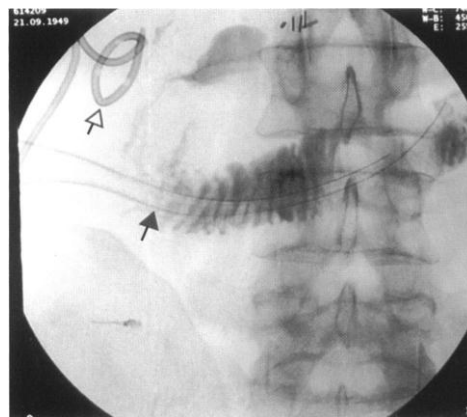


Fig. (5) Contrast study via abdominal tube drain , demonstrating that the tip of the drain lies within the third part of the duodenum (arrowed) (*Memon and Siddiqui ; 2004*).

Serosal injury of the bowel , suture line defect , tight suture causing ischemic necrosis . Unapparent injury to mesenteric vessels , poor haemostasis resulting in a peri-suture haematoma , and a loop of intestine caught in a fascial suture (*Falconiand Pederzoli , 2001*).

When a small bowel anastomosis fails because of technical error , the leak almost invariably occurs at the mesenteric border , where the

serosa has not been adequately cleared of blood vessels and fat (*Carol , 2002*).

The time elapsed to fistula appearance is an important guide line for management and prognosis . Early fistulae arising in the first 48hours post surgery can be considered as technical errors (*Sloan et al ; 2002*).

b- Local disease in GIT :

The risk is greatest for operations performed for inflammatory bowel disease (I.B.D.) , ischemia , malignancy , or extensive intestinal adhesions (*Foster and Lefor , 2001*).

Associated sepsis is important factor in the development and maintenance of fistula (*Rollandelli and joel, 1996*).

Distal obstruction , with increased pressure proximal to the obstruction , leading to leakage at the weakest point (*Gonzalez and Moreno , 2002*).