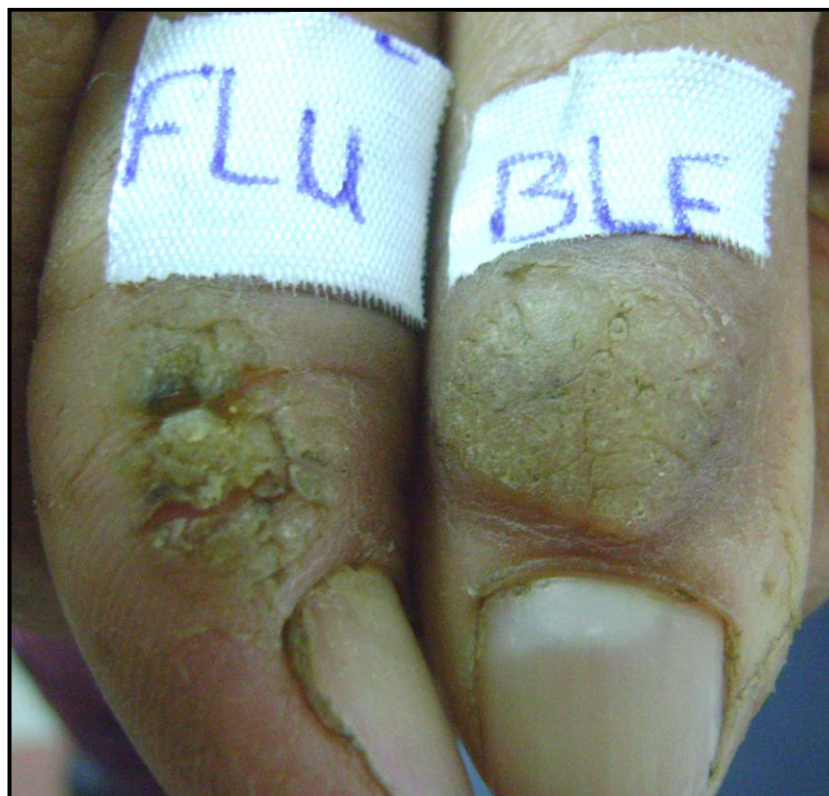
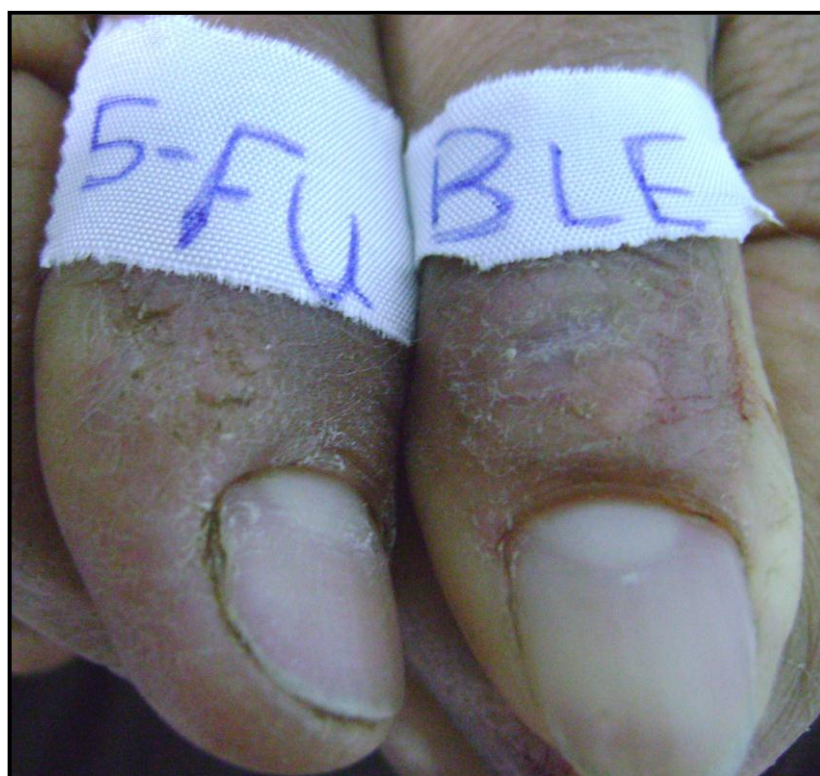
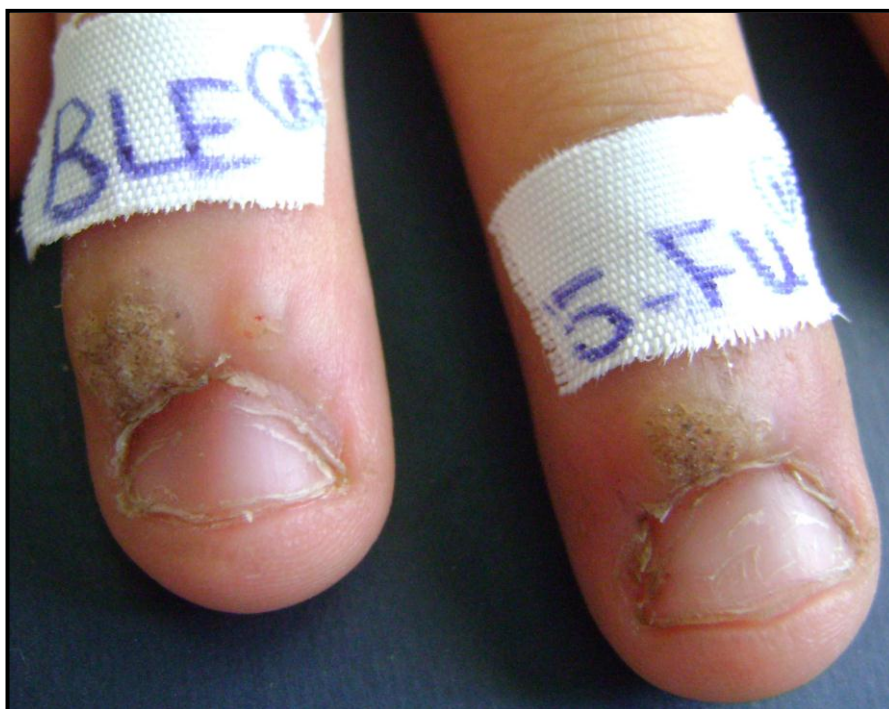

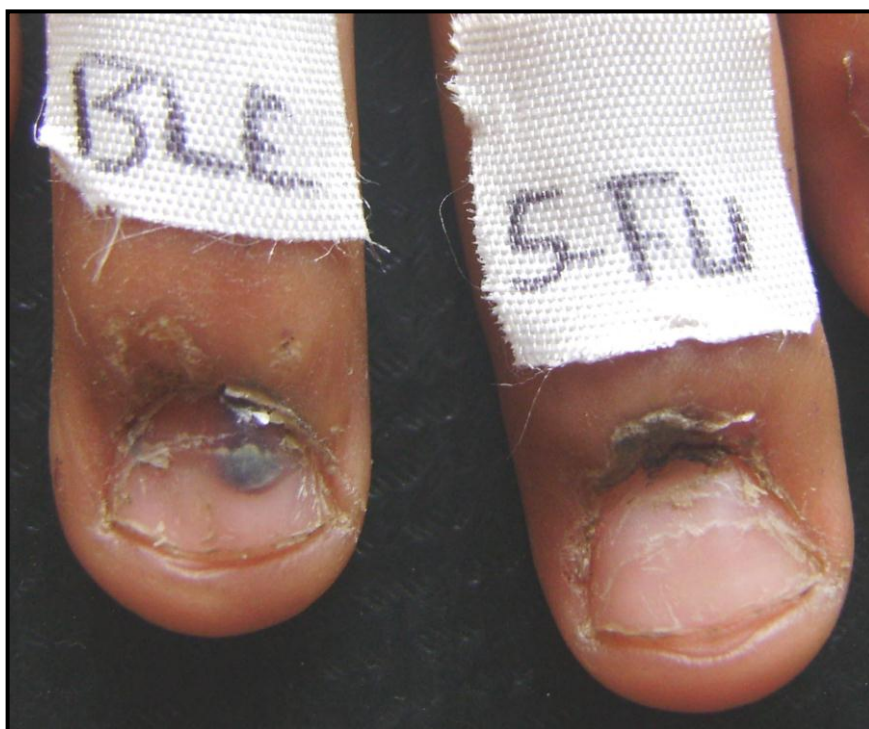**Fig. (11): Two periungual warts in the 1<sup>st</sup> visit before 5-FU and bleomycin injections.**



**Fig. (12): The same patient in the 3<sup>rd</sup> visit (after 2 injections) showing complete response of both 5-FU and bleomycin injected warts.**

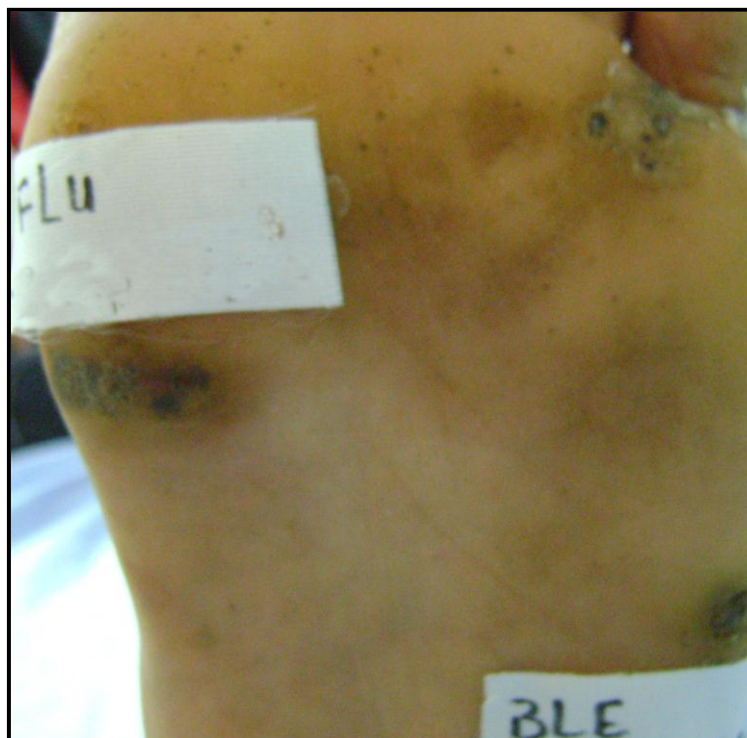


**Fig. (13): Two periungual warts in the 1<sup>st</sup> visit before 5-FU and bleomycin injections.**

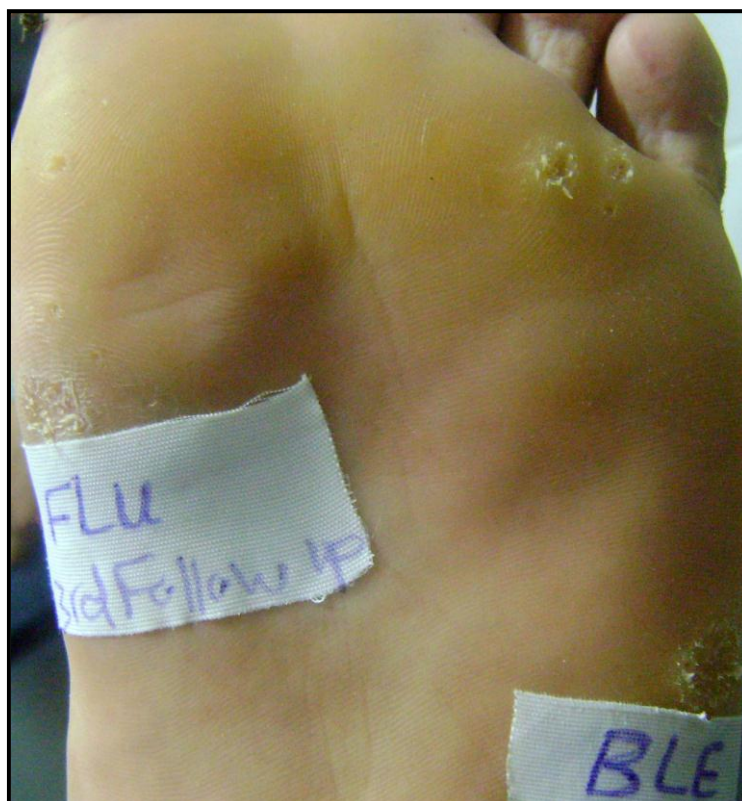

**Fig. (14): The same patient in the 4<sup>th</sup> visit (after 3 injections) showing complete response in both bleomycin and 5-FU injected wart.**

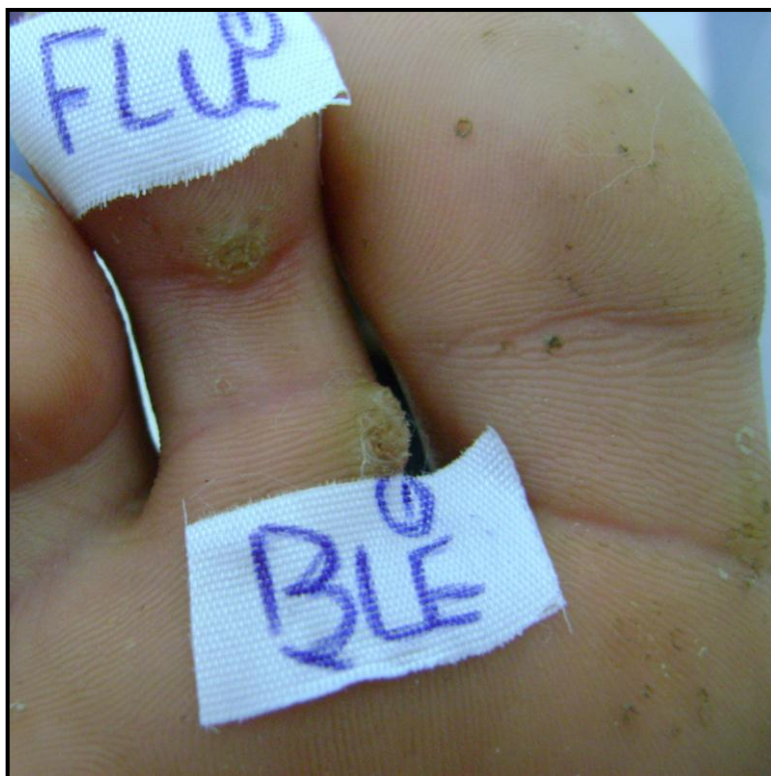



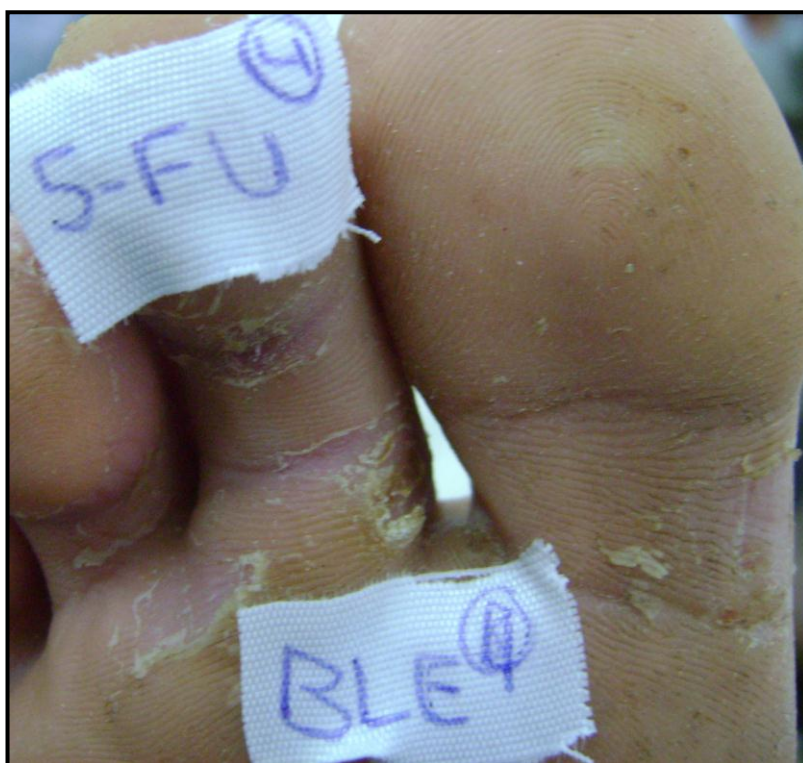**Fig. (15):** Two plantar warts in the 1<sup>st</sup> visit before 5-FU and bleomycin injections.



**Fig. (16):** The same patient in the 3<sup>rd</sup> visit (after 2 injections) showing complete response in both bleomycin and 5-FU injected warts.

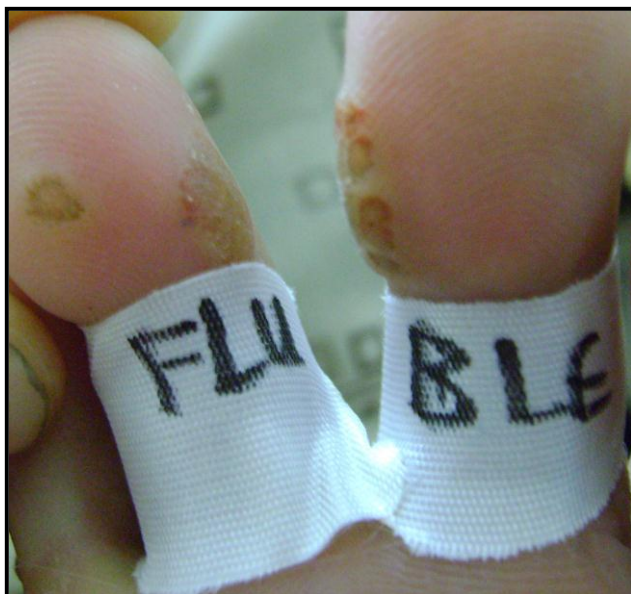

**Fig. (17): Two plantar warts in the 1<sup>st</sup> visit before 5-FU and bleomycin injections.**

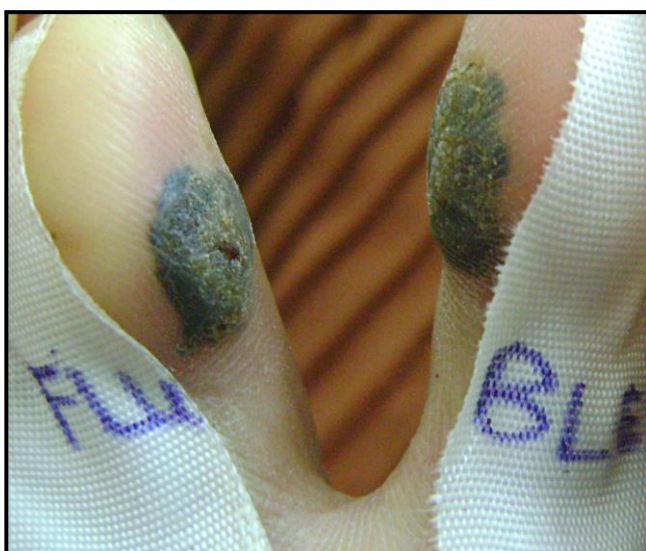

**Fig. (18): The same patient in the 4<sup>th</sup> visit (after 3 injections) showing complete response in both bleomycin and 5-FU injected warts.**

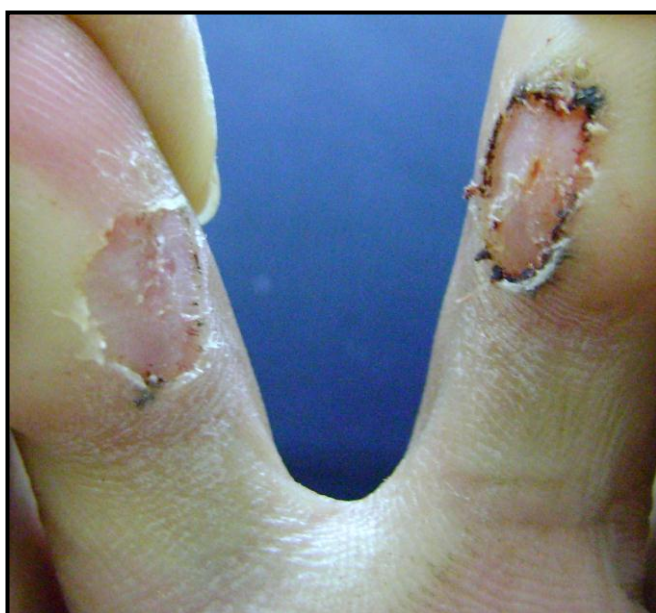



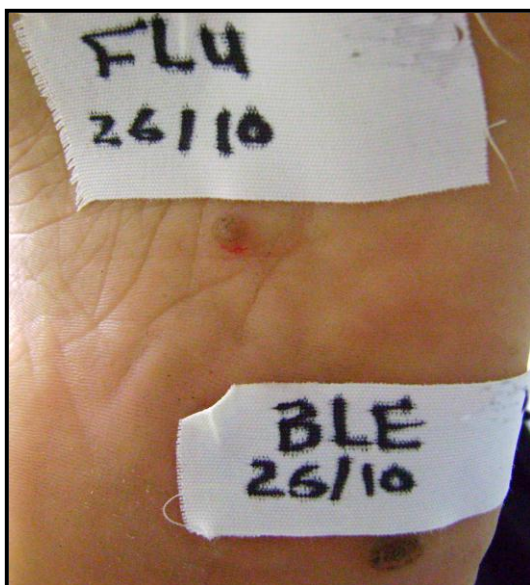**Fig. (19):** Two plantar warts in the 1<sup>st</sup> visit before 5-FU and bleomycin injections.



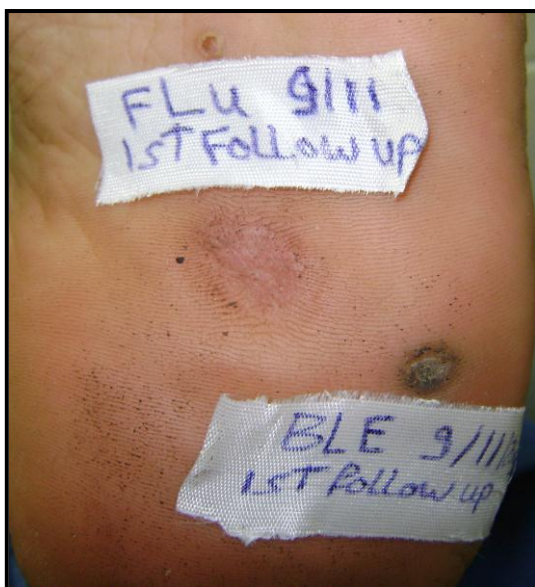**Fig. (20):** The same patient showing blackening of the two warts in the 2<sup>nd</sup> visit (after 1 injection).



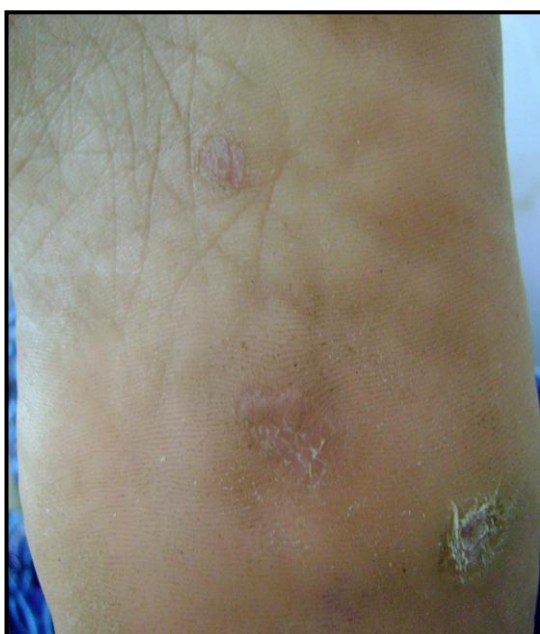**Fig. (21):** The same patient after removal of the black tissue showing complete response.



**Fig. (22):** Two plantar warts in the 1<sup>st</sup> visit.

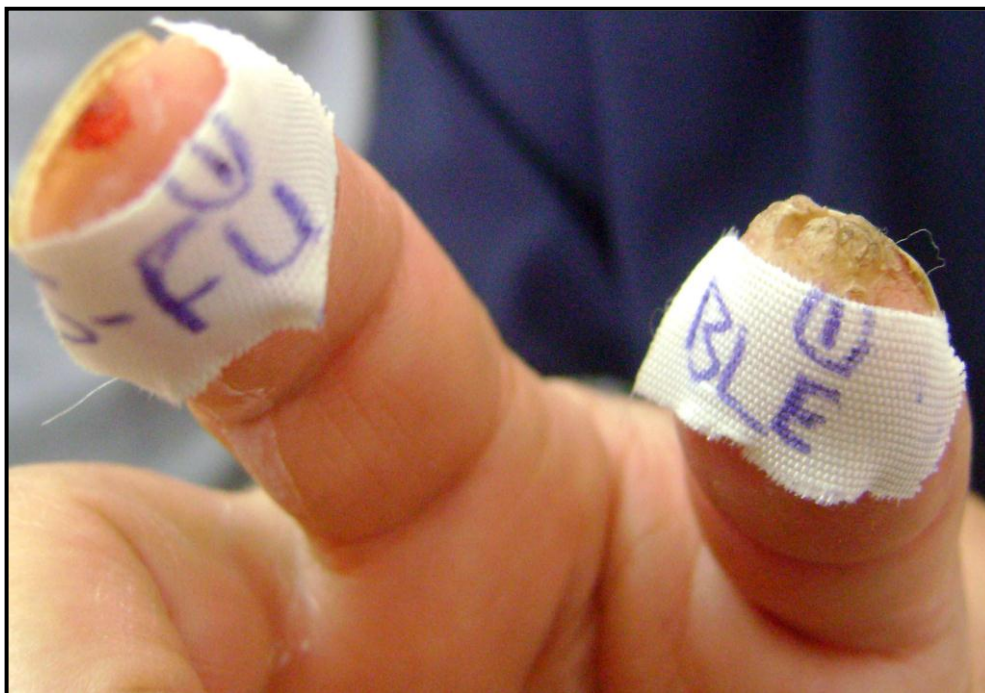

**Fig. (23):** The same patient in the 2<sup>nd</sup> visit (after 1 injection) showing complete response of the 5-FU injected wart and partial response of the bleomycin injected wart.



**Fig. (24):** The same patient in the 3<sup>rd</sup> visit (after 2 injections) showing complete response in both bleomycin and 5-FU injected warts.

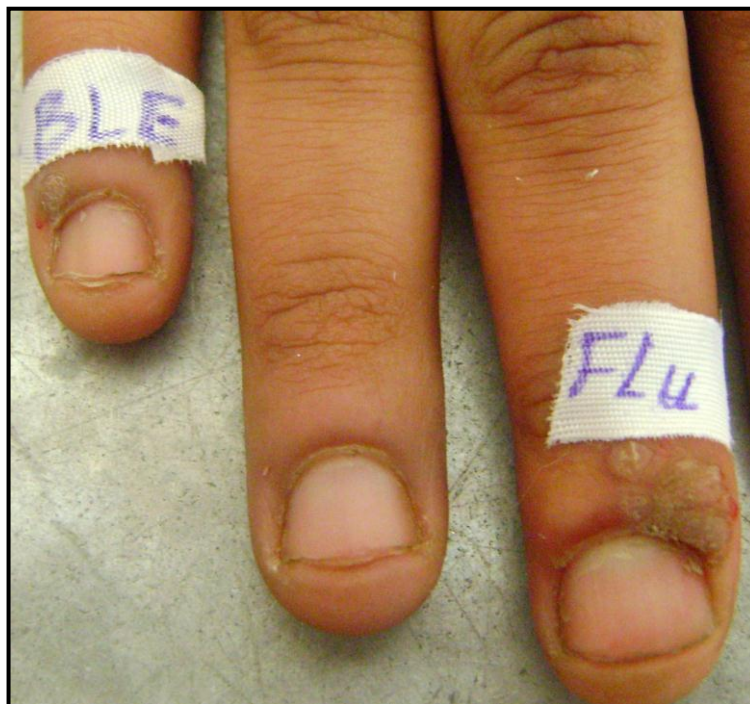



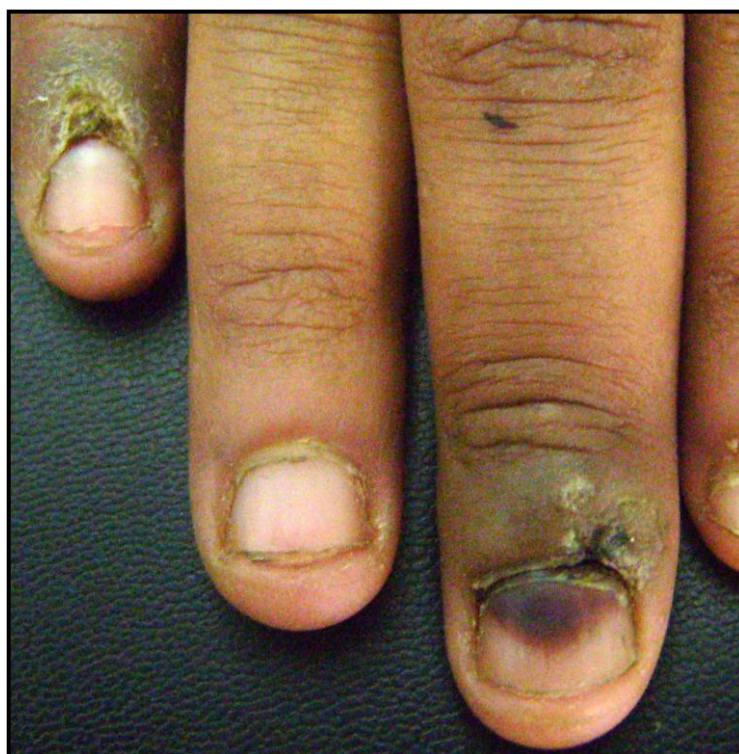**Fig. (25): Two periungual warts in the 1<sup>st</sup> visit.**



**Fig. (26): The same patient in the 2<sup>nd</sup> visit (after 1 injection) showing bullae in the bleomycin injected wart and complete response of the 5-FU injected wart.**

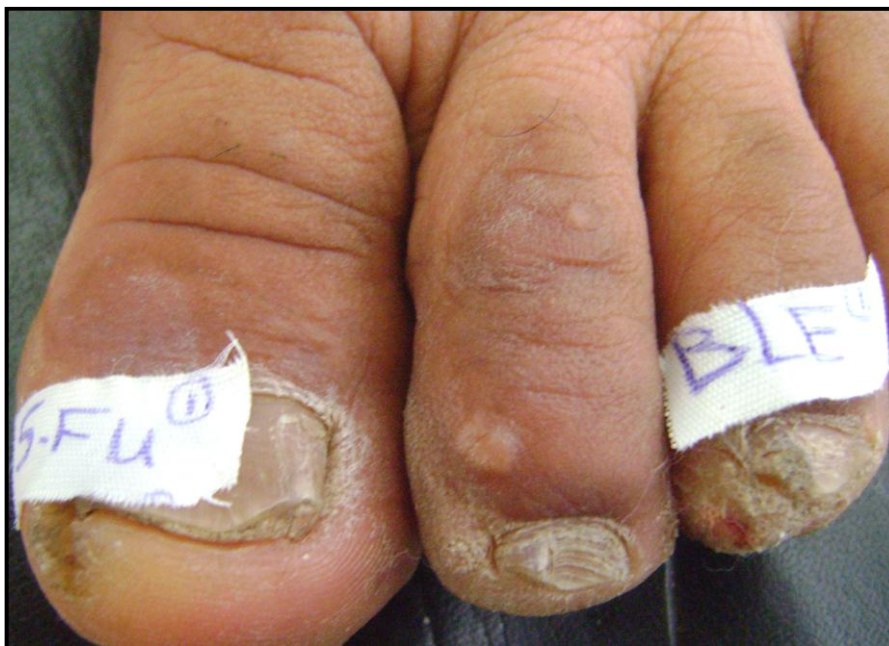

**Fig. (27):** Two periungual warts in the 1<sup>st</sup> visit.

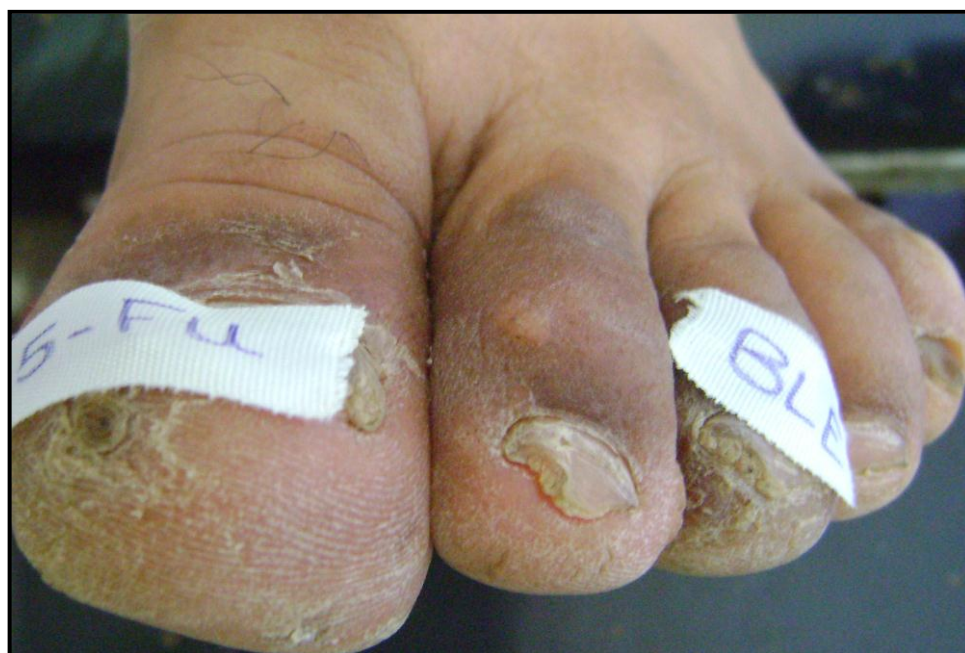

**Fig. (28):** The same patient in the 3<sup>rd</sup> visit (after 2 injections) showing blackening of the nail after 5-FU injection.

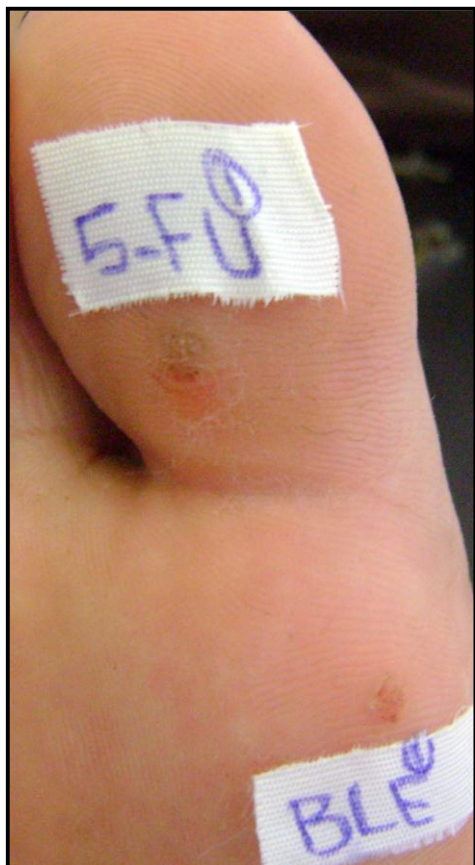



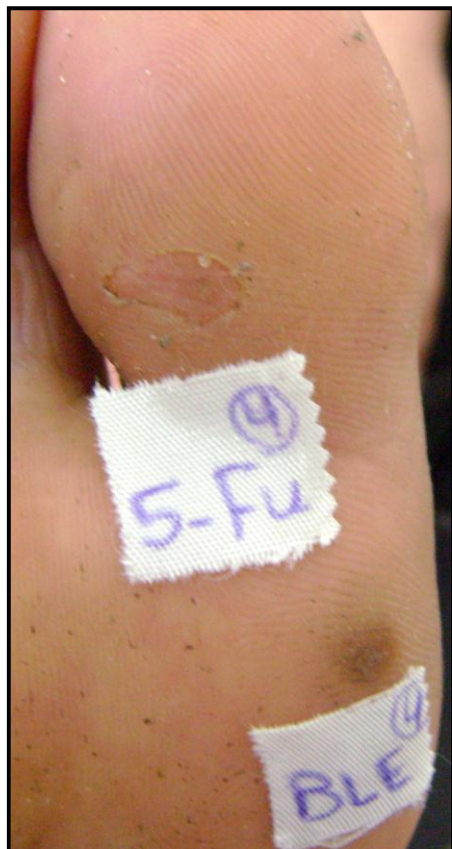**Fig. (29): Two periungual warts in the 1<sup>st</sup> visit.**



**Fig. (30): The same patient in the 5<sup>th</sup> visit (after 4 injections) showing partial response in both bleomycin and 5-FU injected wart.**



**Fig. (31): Two plantar warts before 5-FU and bleomycin injections.**



**Fig. (32): The same patient in the 4<sup>th</sup> visit (after 3 injections) showing complete response of the 5-FU injected wart and partial response.**